



## Review Article

### Sampson's Artery Revisited

Jennifer WH Wong\*, Tiffany S Lai and Michael E Carney

Department of Obstetrics, Gynecology, and Women's Health, John A. Burns School of Medicine, University of Hawaii at Manoa, Honolulu, Hawaii

#### Abstract

This article is a literature review on Sampson's artery. Despite its popularity among gynecologists, not much is known about this artery. It is considered a physiologically insignificant artery located below the round ligament but can serve as a source of severe bleeding. Namesake Dr. John A. Sampson was a predominant gynecologist who studied pelvic anatomy and coined the term "endometriosis". A study at the University of Hawaii John A. Burns School of Medicine revealed that only 41% of medical students were able to identify Sampson's artery. Many anatomy text books fail to acknowledge Sampson's artery, which could explain its obscurity and popularity among gynecologists as a secret artery.

**Keywords:** Anatomy; Arteries; Gynecology; History; Round ligaments

#### Introduction

In the field of obstetrics and gynecology, attending physicians often ask their medical students and residents to identify an artery below the round ligament. This artery, Sampson's artery, has been shared with many generations of medical students, and remains a favorite in gynecologic pelvic anatomy. Despite its popularity among gynecologists, not much is known about the artery itself or its namesake. In reviewing the current medical literature, there are only two publications that directly address Sampson's artery. These publications are discussed below.

#### Sampson's artery

Sampson's artery, also known as the artery of the round ligament of the uterus, runs below the round ligament to create an anastomosis between the uterine artery and ovarian artery (Figures 1,2). The embryonic origin of Sampson's artery remains unknown. Physiologically, Sampson's artery is considered insignificant because its blood supply to the ovaries is minimal compared to that of the ovarian arteries.

Although physiologically insignificant, Sampson's artery can have large clinical implications and cause significant bleeding if injured. Two unrelated case studies have reported avulsion of the round

\*Corresponding author: Jennifer WH Wong, Department of Obstetrics, Gynecology, and Women's Health, John A Burns School of Medicine, University of Hawaii at Manoa, Honolulu, Hawaii, Tel: +808 2276712; E-mail: jwhwong@hawaii.edu

**Citation:** Wong JWH, Lai TS, Carney ME (2017) Sampson's Artery Revisited. J Reprod Med Gynecol Obstet 2: 005.

**Received:** March 15, 2017; **Accepted:** June 03, 2017; **Published:** June 19, 2017

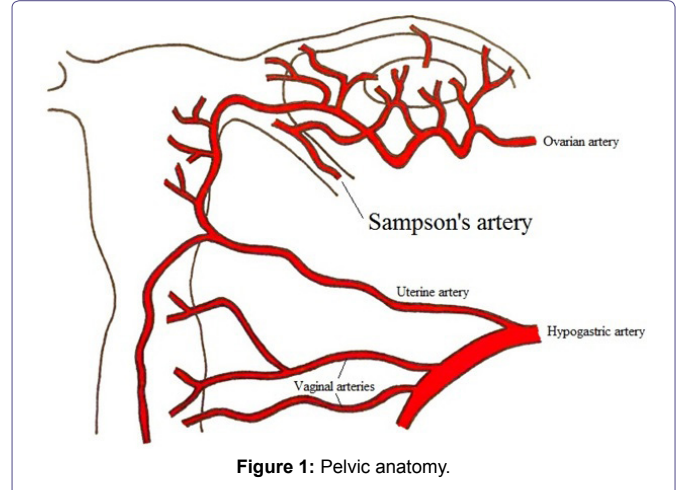


Figure 1: Pelvic anatomy.

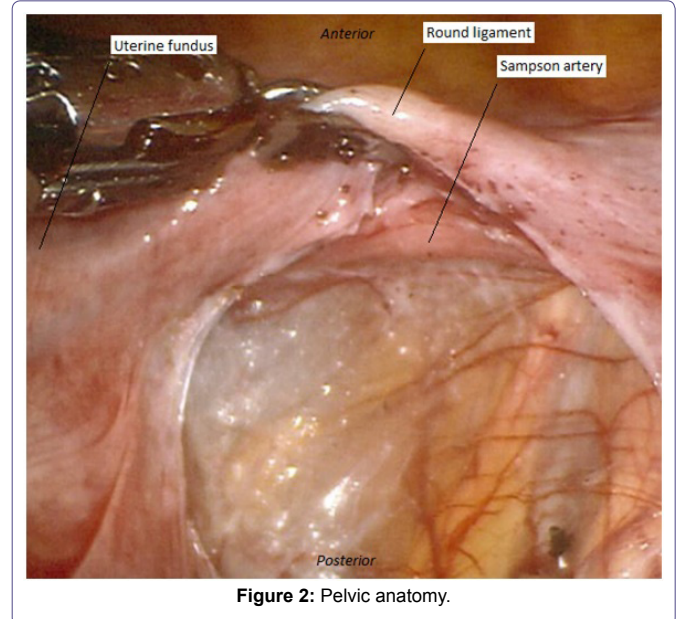


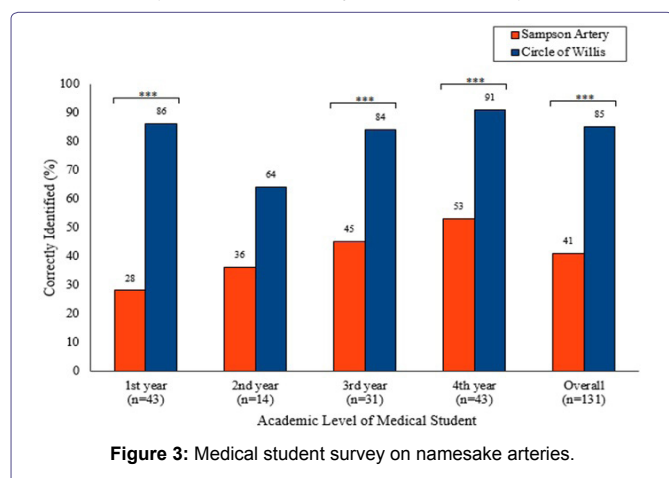
Figure 2: Pelvic anatomy.

ligament with damage to Sampson's artery following an inguinal hernia repair. In these two cases, the bleeding from Sampson's artery necessitated a return to the operating room with evacuation of 1 liter of hemoperitoneum [1,2]. While general surgeons rarely handle Sampson's artery, they ideally should be familiar with the vessel given the serious sequela associated with an unrecognized injury to Sampson's artery. Gynecologists often encounter Sampson's artery, and it must be carefully ligated during hysterectomies. In general, physicians must beware of this tiny, but potentially large, bleeder.

#### Awareness in today's society

A study was performed at the University of Hawaii John A. Burns School of Medicine to assess medical student awareness of Sampson's artery in comparison to that of another namesake artery. A questionnaire was anonymously emailed to the medical students with a 50%

response rate. The questionnaire stated “The circle of Willis is associated with the: a) brain, b) heart, c) liver, d) kidneys, e) small bowel, f) penis, g) uterus”. The same question and answer choices were repeated for Sampson's artery. Data showed that only 41% of medical students were able to identify Sampson's artery, which was significantly less than the 85% of medical students who were able to identify the circle of Willis (chi-squared,  $p < 0.01$ ). When data were analyzed according to the respondent's academic level, there was a significant difference in identification of Sampson's artery and circle of Willis among the first, third, and fourth year medical students (chi-squared,  $p < 0.01$ ) (Figure 3). This gap in medical knowledge comes as no surprise considering many anatomy texts, including the atlas of human anatomy and grant's atlas of anatomy, fail to acknowledge Sampson's artery [3,4].



### Dr. Sampson's work

Sampson's artery was named in honor of Dr. John A. Sampson (August 17, 1873-December 23, 1946) (Figure 4), a gynecologist who graduated from the John Hopkins School of Medicine and was appointed professor of Gynecology at the Albany Medical College. Dr. Sampson is best known for his extensive research on endometriosis. He was among the first to study this enigmatic disease that afflicts many women. He coined the terms “endometriosis” and “chocolate cysts”, in addition to proposing the theory of retrograde menstruation [5,6]. Dr. Sampson also showed great interest oncology. He described the delicate intricacies of the pelvic vasculature and lymphatic, and he highlighted the importance of the ureteral bloody supply in radical surgery for cervical cancer [7,8].

### Conclusion

Namesake Dr. John A. Sampson has contributed much knowledge to the field of gynecology. While deemed physiologically insignificant by many textbooks and even disregarded in others, Sampson's artery is



**Figure 4:** Dr. John A. Sampson.

small but mighty. If accidentally severed, it can result in profuse bleeding and potentially death. So why is this tiny artery so popular among gynecologists? Perhaps it is the hidden power and obscurity-shared in the operating room amongst ourselves, passed down from generation to generation, that it remains one of a gynecologist's favorite secrets.

### Acknowledgement

The authors would like to thank the medical students at the University of Hawaii John A. Burns School of Medicine who participated in our survey.

### References

- Buch KE, Reiner M, Divino CM (2007) Hemoperitoneum following inguinal hernia repair: a case report. *Hernia* 11: 459-461.
- Boachie JA, Smith-Singares E (2016) Sampson's artery hemorrhage after inguinal hernia repair: second case reported. *Case Reports Surg* 2016: 2534037.
- Netter F (2014) *Atlas of Human Anatomy* (6th edn). Elsevier Inc, Amsterdam, Netherlands, Europe.
- Agur AMR, Dalley AF (2012) *Grant's Atlas of Anatomy* (13th edn). Philadelphia, Pennsylvania, US.
- Sampson JA (1921) Perforating hemorrhagic (chocolate) cysts of the ovary. *Am J Obstet Gynecol* 2: 526-528.
- Sampson JA (1927) Peritoneal endometriosis due to the menstrual dissemination of endometrial tissue into the peritoneal cavity. *Am J Obstet Gynecol* 14: 422-469.
- Dastur AE, Tank PD (2010) John A Sampson and the origins of endometriosis. *J Obstet Gynaecol India* 60: 299-300.
- Speert H (1958) *Obetetric and Gynecologic Milestones: Essays in Eponymy*. Macmillan, London, England, UK.