



Case Report

Bilateral Pleural Effusion as Unique Manifestation of Atypical Ovarian Hyperstimulation Syndrome

Raquel García Guerra*, Laura De La Fuente Bitaine and Nerea Ruiz Azqueta

Department of Obstetrics and Gynecology, Divisions of Reproductive/Infertility Medicine, Hospital Doce de Octubre, Madrid, Spain

Abstract

Ovarian Hyperstimulation Syndrome (OHSS) is a complication associated with *In Vitro* Fertilization (IVF) treatment. The clinical manifestations are due to an increase of vascular permeability and extravasations of fluid in a third space. Herein we report an unusual case of OHSS revealed by an isolated bilateral pleural effusion. A 37-year-old patient presented with dyspnea and orthopnea in addition to dry cough and chest pain 2 weeks after an IVF cycle with 13 oocytes retrieved, E2: 2435 pg/ml and 2 cleavage stage embryo transferred. Patient was afebrile, tachycardic, tachypneic with normal oxygen saturation. Decreased breath sounds of both lung bases were detected. Laboratory tests showed Albumin 2.8 g/dl, Human Chorionic Gonadotropin (hCG) 1494 mU/ml, fibrinogen > 500 mg/dl, D-Dimer 666 ng/ml. Hematocrit, renal and liver function tests were in normal range. Electrocardiogram was normal. Transvaginal sonography did not show free fluid. Chest X-ray revealed bilateral pleural effusion and angio-CT discarded Pulmonary Embolism (PE). Patient was admitted to the intensive care unit for seven days. She was symptomatically treated with intravenous diuretics and albumin, oxygen and low molecular weight heparin with a good recovery. Then she was discharged on the thirteenth day. Three days after she was re-admitted for chest pain without any other symptoms. PE was discarded again with a lung scintigraphy and pleural effusion persisted in Chest X-ray. The patient improved after 2 days of symptomatic management. A single intrauterine gestational sac was seen but it ended in miscarriage at 8 weeks. Severe OHSS is a life-threatening complication that requires an early diagnosis and treatment.

Introduction

Ovarian Hyperstimulation Syndrome (OHSS) is a complication associated with *In Vitro* Fertilization (IVF) treatment. The overall incidence is 0.5-10%, although depending on the severity it may vary

*Corresponding author: Raquel García Guerra, Department of Obstetrics and Gynecology, Divisions of Reproductive/Infertility Medicine, Hospital Doce de Octubre, Madrid, Spain, Tel: +0034695307682; E-mail: raquelgague@hotmail.com

Citation: Guerra RG, De La Fuente Bitaine L, Azqueta NR (2017) Bilateral Pleural Effusion as Unique Manifestation of Atypical Ovarian Hyperstimulation Syndrome. J Reprod Med Gynecol Obstet 2: 004.

Received: March 31, 2017; Accepted: May 11, 2017; Published: May 26, 2017

from 33% in mild, 4% in moderate and 0.5-1% in severe cases [1]. Its etiology and pathogenesis are still uncertain but clinical manifestations are due to an increase of vascular permeability and extravasation of fluid in a third space [2,3]. Ascites is usual, however, pleural effusion is uncommon as isolated manifestation [4-6]. It may be present in 10-29% of severe OHSS associated with other symptoms. We present an extremely rare presentation of late OHSS where respiratory manifestations secondary to bilateral pleural effusion were the only symptom.

Case Report

A 37-year-old woman with no relevant past medical history other than primary infertility was referred to assessment. IVF was indicated because of asthenozoospermia and low ovarian reserve. Pregnancy was achieved by *In Vitro* Fertilization-Intra Cytoplasmic Sperm Injection (IVF-ICSI) after a cycle of stimulation using an antagonist protocol, with initial dose of 150 IU of Human Recombinant Follicle Stimulating Hormone (rhFSH) and 75 IU of Human Menopausal Gonadotropin (hMG) daily. The patient received a total of 1000 IU of FSH and 675 IU of hMG over 9 days. Transvaginal sonography revealed 13 follicles with serum estradiol level of 2435 pg/ml and progesterone 0.58 ng/ml. On the same day 10.000 IU of Human Chorionic Gonadotropin (hCG) was administered. We retrieved 13 oocytes and ICSI procedure end up with 8 embryos, of which 2 cleavage mild quality embryos were transferred on day 3. Luteal phase supplementation was performed with vaginal progesterone.

The patient presented two weeks after embryo transfer with a four-day history of dyspnea and orthopnea in addition to dry cough and chest pain. She did not report nausea, vomiting, abdominal pain or distention, neither weight gain nor other symptoms. On physical examination patient was alert, oriented and well hydrated. She was afebrile, tachycardic and tachypneic with normal oxygen saturation and arterial blood pressure of 131/95 mmHg. Auscultation revealed decreased breath sounds to the bases bilaterally. The abdomen was soft on palpation without sign of ascites. The rest of examination was normal.

Blood analysis showed: Hemoglobin 13.8 g/dl, hematocrit 41.5%, leukocytes 13060/mcl, neutrophils 79.9%, creatinine 0.82 mg/dl, albumin 2.8 g/dl, sodium 136 mmol/L, potassium 3,9 mmol/L, hCG 1494 mU/ml. Coagulation was normal except fibrinogen levels greater than 500 mg/dl and D-Dimer 666 ng/ml. Liver function tests were in normal range. Electrocardiogram was normal. Transvaginal ultrasound showed no intraperitoneal fluid, but ovaries were moderately enlarged (left: 76x65 mm; right: 56x65 mm). Chest X-ray revealed bilateral pleural effusion and angio-CT scan confirmed bilateral pleural effusion with maximum column of 9 cm on the right side and 4 cm on the left side (Figure 1) and a small amount of perihepatic free fluid (Figure 2). Angio-CT scan discarded Pulmonary Embolism (PE).

Patient was admitted to the Intensive Care Unit for seven days. She was symptomatically treated with intravenous diuretics, albumin, oxygen and low molecular weight heparin for thromboembolic prophylaxis. Patient remained hemodynamically stable, afebrile, with normal urine output and negative fluid balance, with improvement in respiratory symptoms, so that oxygen therapy was reduced and chest tube

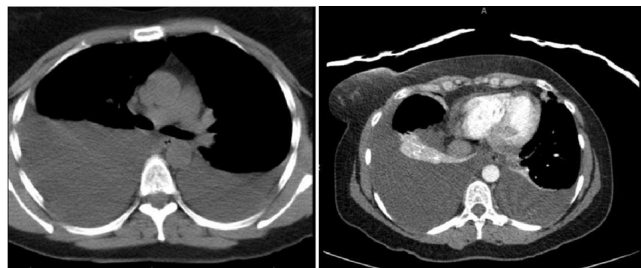


Figure 1: Angio-CT scan performed on the patient (bilateral pleural effusion).

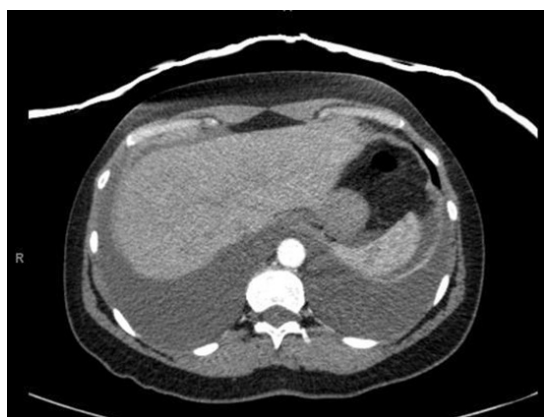

Figure 2: Angio-CT scan performed on the patient (bilateral pleural effusion and a small amount of perihepatic free fluid).

insertion was not needed. Blood analysis before discharge showed BHCG (Human Chorionic Gonadotropin) rising and normal levels of albumin, creatinine and ions. Ultrasound revealed an intrauterine gestational sac with an embryo of 2 mm without heartbeat. There was still no free abdominal fluid. She was discharged feeling well on the thirteenth day.

Three days after, she was readmitted for chest pain without any other symptoms. Blood test showed: sodium 148 mEq/l, with normal hematocrit, renal and liver function. D-Dimer: 1095 ng/ml. Pulmonary embolism was discarded again with lung scintigraphy and pleural effusion persisted in Chest X-ray, though less important than previously. Biochemical analysis of pleural fluid examined after thoracentesis (50cc of serous fluid) was compatible with exudates. Cytological evaluation was negative for malignancy and microbiological analysis discarded infection. Probably the origin of this clinical case was related with the physiopathology of the OHSS. The patient improved after 2 days of symptomatic management with oxygen therapy. She was assessed 10 days after discharge (8+2 weeks of pregnancy), with complete symptoms resolution. In ultrasound a single intrauterine gestational sac was seen with and embryo of 3 mm without a heartbeat, so miscarriage was diagnosed.

Discussion

Although the etiology of OHSS is unknown, the physiopathology is an increase of vascular permeability to high molecular weight proteins due to mediators such as Vascular Endothelial Growth Factor (VEGF), produced by granulosa cells, which depends on hCG [2,4,7,8]. This causes displacement of fluids and proteins from intravascular space to third space, with intravascular volume depletion, hypotension, oliguria, ascites and hemoconcentration [4]. It is proposed that pleural effusion could be secondary to transfer of ascites fluid

through the diaphragmatic lymphatic or diaphragmatic anatomical defects, which are more frequent on the right side of the diaphragm [6-12].

Predisposing factors for OHSS includes: age under 35 years, number of follicles over 15, plasma concentration of estradiol higher than 3,000 pg/ml, polycystic ovary syndrome and pregnancy [10,11,13]. None of them was relevant in our case and atypical OHSS could only be associated to pregnancy and a particular patient reliability. Given the possible recurrence of the syndrome in future cycles of stimulation in this patient, it will be necessary to consider preventive measures, such as: cancel the cycle before administering hCG with less follicles or lower levels of estradiol to the previous cycle; reduce dose of hCG; embryo cryopreservation to avoid the production of endogenous hCG; and delayed transfer [8,14]. Other secondary prophylaxis strategies (albumin administration, corticosteroids or dopamine agonists) are controversial [14,15].

Conclusion

Isolated pleural effusion is an uncommon feature in severe cases of OHSS. It is a life-threatening complication that has to be differentiated from pulmonary embolism, a common complication associated with hyperestrogenism situations [11]. Physicians should be aware of this complication and keep in mind that it may occur without other most common symptoms. Early diagnosis and treatment is crucial to enhance patient recovery. We must prevent its occurrence analyzing the risk factors of each patient and developing an individualized treatment plan.

References

1. Royal College of Obstetricians and Gynecologists (2016) The Management of Ovarian Hyperstimulation Syndrome. Royal College of Obstetricians and Gynecologists, London, UK.
2. Gomez R, Soares SR, Busso C, Garcia-Velasco JA, Simon C, et al. (2010) Physiology and pathology of ovarian hyperstimulation syndrome. *Semin Reprod Med* 28: 448-457.
3. Delvigne A, Rozenberg S (2003) Review of clinical course and treatment of Ovarian Hyperstimulation Syndrome (OHSS). *Hum Reprod Update* 9: 77-96.
4. Srivali N, Thongprayoon C, Cheungpasitporn W, Ungprasert P and Caples SM (2016) Unusual cause of pleural effusion: ovarian hyperstimulation syndrome. *QJM* 109: 197-198.
5. Beji O, Brahmi N, Thabet H, Mokline A, Abidi N, et al. (2008) Compressive pleural effusion after ovarian hyperstimulation syndrome-a case report and review. *Fertil Steril* 89: 1-3.
6. George K, Aleyamma TK, Kamath M, Chandy A, Mangalaraj AM et al. (2010) Symptomatic unilateral pleural effusion: A rare presentation of ovarian hyperstimulation syndrome. *J Hum Reprod Sci* 3: 49-51.
7. Grove CS, Lee YC (2002) Vascular endothelial growth factor: the key mediator in pleural effusion formation. *Curr Opin Pulm Med* 8: 294-301.
8. Yildizhan R, Adali E, Kolusari A, Kurdoglu M, Ozgokce C, et al. (2008) Ovarian Hyperstimulation Syndrome with pleural effusion: a case report. *Cases* 1: 323.
9. Loret de Mola JR, Friedler S (1999) Pathophysiology of unilateral pleural effusions in the ovarian hyperstimulation syndrome. *Hum Reprod* 14: 272-273.
10. Mullin CM, Fino ME, Reh A, Grifo JA, Licciardi F (2011) Symptomatic Isolated Pleural Effusion as an Atypical Presentation of Ovarian Hyperstimulation Syndrome. *Case Rep Obstet Gynecol*.
11. Aldawood AS, Felemban AA (2003) Isolated unilateral pleural effusion as the only manifestation of the ovarian hyperstimulation syndrome. *Saudi Med J* 24: 1397-1399.

12. Gupta S, Sathya B, Padhy N, Kundavi S, Thomas BE, et al. (2009) Isolated bilateral pleural effusion as the sole manifestation of late onset ovarian hyperstimulation syndrome. *J Hum Reprod Sci* 2: 83-86.
13. Whelan JG, Vlahos NF (2000) The ovarian hyperstimulation syndrome. *Fertil Steril* 73: 883-896.
14. Mathur RS, Tan BK (2014) British Fertility Society Policy and Practice Committee: Prevention of Ovarian Hyperstimulation Syndrome, *Hum Fertil (Camb)* 17: 257-268.
15. Gomez R, Soares SR, Busso C, Garcia-Velasco JA, Simon C, et al. (2010) Physiology and pathology of ovarian hyperstimulation syndrome. *Semin Reprod Med* 28: 448-457.