

Case Report

Terrien's Marginal Degeneration with Hydrops

Anirudh Duhan*, Eswar Sakare, Sudhakar Potti and Madhuri Venigalla

Sankara Eye Hospital, Pedakakani, Guntur, Andhra Pradesh, India

Abstract

We report a case of bilateral Terrien's Marginal Degeneration with Hydrops. A 59 year old man presented with diminution of vision in both eyes since 3 years. On examination both eyes had superior ectatic changes with right eye having scarred Descemet's membrane indicating a healed hydrops and left eye showing superior corneal edema indicating resolving hydrops.

Keywords: Anterior segment; Cornea; Ectasia; Hydrops; Terrien's

Background

Terrien's Marginal Degeneration (TMD) is a rare, slowly progressive, peripheral corneal ectasia of unknown etiology. The condition is most commonly seen in males past the age of 40. Initially, TMD presents as small, yellow-white, stromal opacities composed of lipids with some superficial vascularization, which begins superiorly and spreads circumferentially. With progression, a gutter forms in the affected area due to stromal thinning, leaving the epithelium intact. The condition is often bilateral and asymmetric. Perforation of the cornea is rare but may occur spontaneously or secondary to trauma. Patients are often asymptomatic but may complain of mild irritation or vision changes due to increasing against-the-rule or oblique astigmatism. Very few cases have been reported of hydrops in TMD.

Case Description

A 59 year male presented with diminution of vision in both eyes since 3 years. There was no history of trauma and no significant family history. His best corrected visual acuity was 6/24 (+5.50D/-10.0D/90) and *Hand movement close to face* with no improvement with glasses in right and left eye respectively. Slit lamp examination revealed superior ectatic changes in right eye with scarred Descemet's

*Corresponding author: Anirudh Duhan, Sankara eye hospital, Pedakakani, Guntur, Andhra Pradesh, India, Tel: +91 8471873639; E-mail: anirudhduhan@gmail.com

Citation: Duhan A, Sakare E, Potti S, Venigalla M (2021) Terrien's Marginal Degeneration with Hydrops. J Ophthalmic Clin Res 8: 087.

Received: September 12, 2021; **Accepted:** September 21, 2021; **Published:** September 28, 2021

Copyright: © 2021 Duhan A, et al. This is an open-access article distributed under the terms of the Creative Commons Attribution License, which permits unrestricted use, distribution, and reproduction in any medium, provided the original author and source are credited.

Membrane (DM) and left eye revealed superior ectatic changes with edema. Right eye had senile immature cataract and left eye presented with senile mature cataract. Right eye fundus examination revealed no abnormalities; left eye fundus could not be viewed on slit lamp examination. B-scan ultrasound was within normal limits (Figures 1-4).

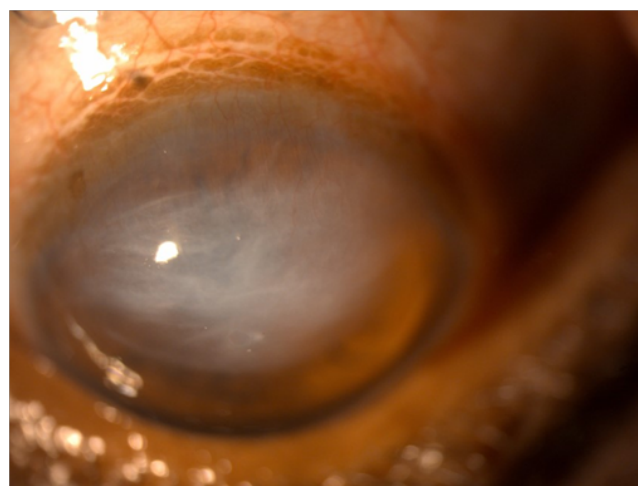


Figure 1: Right eye anterior segment OCT shows stromal scarring in the superior quadrant.

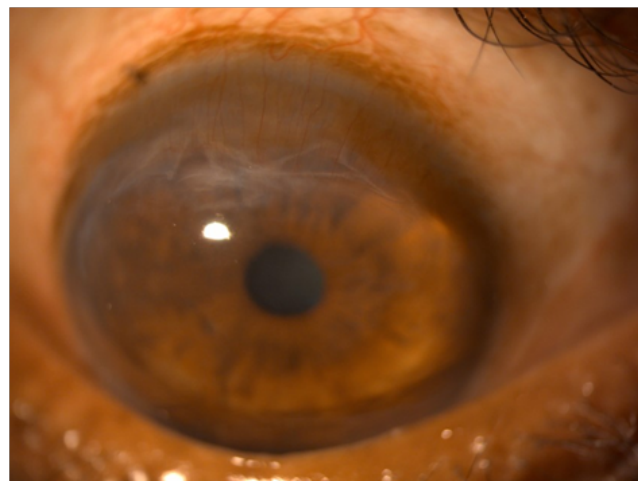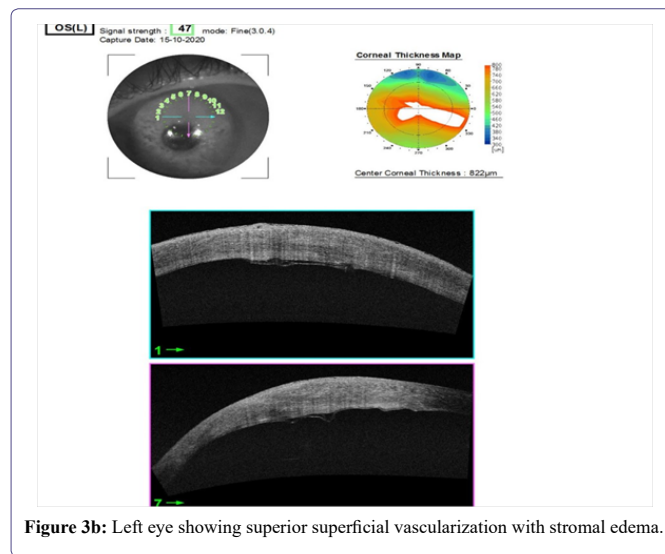
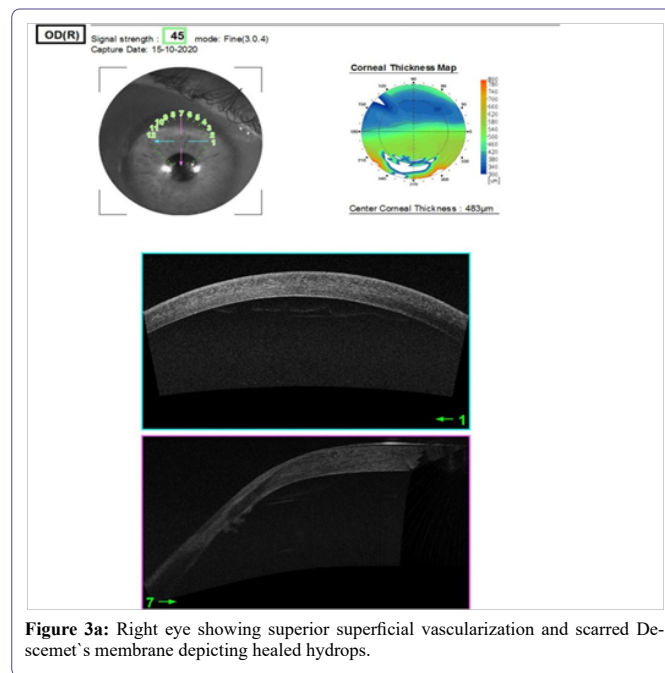


Figure 2: Left eye anterior segment OCT shows increased corneal thickness and Descemet's detachment.

Therapeutic Intervention

Patient was started on Sodium chloride (5%w/v) eye drops 5 times a day in left eye and Carboxy Methyl Cellulose (0.5%w/v) eye drops in both eyes.

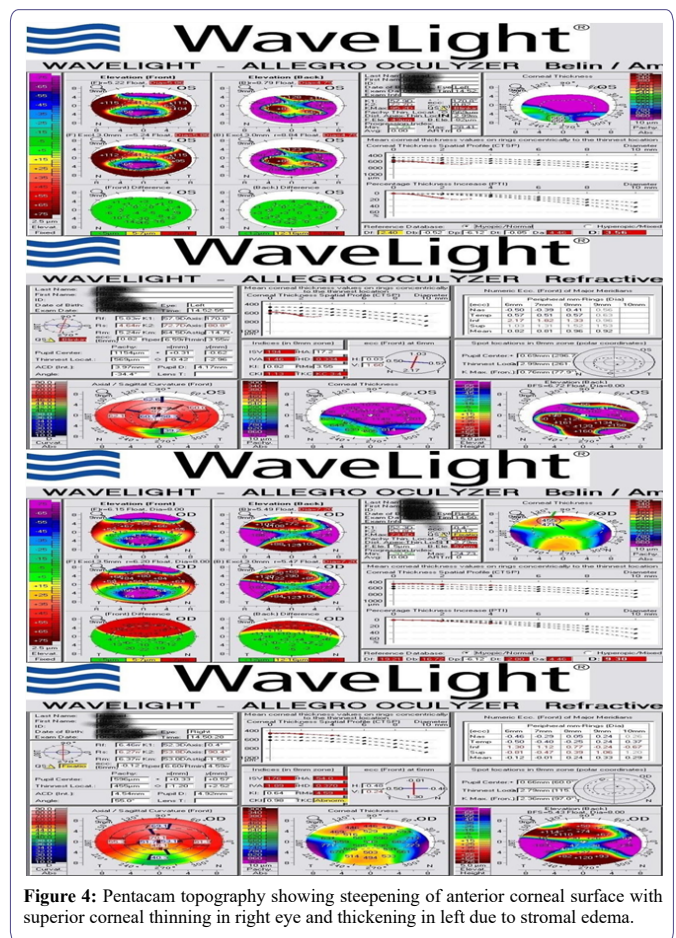
Cataract surgery for left eye was advised to patient once the stromal edema reduces.



Literature Review

Terrien's marginal degeneration is a slowly progressive thinning of the peripheral cornea.

It usually begins superior-nasally and progresses circumferentially. Yellow-white stromal opacities with superficial neovascularization are present. These stromal opacities are composed of scarring and lipid infiltration, and there is a distinct interval between the limbus and site of infiltration. Ultimately, stromal degeneration occurs, causing formation of a peripheral gutter [1]. The exact etiology of TMD is unknown, but there is male predilection (3:1). The condition usually appears in the third to fifth decade of life, but it can occur at any age



[2]. Both eyes are commonly affected, but presentation can be asymmetric [1].

Discussion

Although Terrien's marginal degeneration is rare, it is important that eyecare providers differentiate it from other conditions so they can set patient expectations and initiate proper management and treatment. A thorough case history and careful slit lamp examination are essential.

Conflict of Interest

The Author declares that there is no conflict of interest.

I hereby declare that no funding was received for this work.

References

- Lopez JS, Price FW, Whitcup SM, Li Q, de Smet M, et al. (1991) Immunohistochemistry of Terrien's and Mooren's corneal degeneration. Arch Ophthalmol 109: 988-992.
- Ceresara G, Migliavacca L, Orzalesi N, Rossetti L (2011) In vivo confocal microscopy in Terrien marginal corneal degeneration: a case report. Cornea 30: 820-824.



- Advances In Industrial Biotechnology | ISSN: 2639-5665
- Advances In Microbiology Research | ISSN: 2689-694X
- Archives Of Surgery And Surgical Education | ISSN: 2689-3126
- Archives Of Urology
- Archives Of Zoological Studies | ISSN: 2640-7779
- Current Trends Medical And Biological Engineering
- International Journal Of Case Reports And Therapeutic Studies | ISSN: 2689-310X
- Journal Of Addiction & Addictive Disorders | ISSN: 2578-7276
- Journal Of Agronomy & Agricultural Science | ISSN: 2689-8292
- Journal Of AIDS Clinical Research & STDs | ISSN: 2572-7370
- Journal Of Alcoholism Drug Abuse & Substance Dependence | ISSN: 2572-9594
- Journal Of Allergy Disorders & Therapy | ISSN: 2470-749X
- Journal Of Alternative Complementary & Integrative Medicine | ISSN: 2470-7562
- Journal Of Alzheimers & Neurodegenerative Diseases | ISSN: 2572-9608
- Journal Of Anesthesia & Clinical Care | ISSN: 2378-8879
- Journal Of Angiology & Vascular Surgery | ISSN: 2572-7397
- Journal Of Animal Research & Veterinary Science | ISSN: 2639-3751
- Journal Of Aquaculture & Fisheries | ISSN: 2576-5523
- Journal Of Atmospheric & Earth Sciences | ISSN: 2689-8780
- Journal Of Biotech Research & Biochemistry
- Journal Of Brain & Neuroscience Research
- Journal Of Cancer Biology & Treatment | ISSN: 2470-7546
- Journal Of Cardiology Study & Research | ISSN: 2640-768X
- Journal Of Cell Biology & Cell Metabolism | ISSN: 2381-1943
- Journal Of Clinical Dermatology & Therapy | ISSN: 2378-8771
- Journal Of Clinical Immunology & Immunotherapy | ISSN: 2378-8844
- Journal Of Clinical Studies & Medical Case Reports | ISSN: 2378-8801
- Journal Of Community Medicine & Public Health Care | ISSN: 2381-1978
- Journal Of Cytology & Tissue Biology | ISSN: 2378-9107
- Journal Of Dairy Research & Technology | ISSN: 2688-9315
- Journal Of Dentistry Oral Health & Cosmesis | ISSN: 2473-6783
- Journal Of Diabetes & Metabolic Disorders | ISSN: 2381-201X
- Journal Of Emergency Medicine Trauma & Surgical Care | ISSN: 2378-8798
- Journal Of Environmental Science Current Research | ISSN: 2643-5020
- Journal Of Food Science & Nutrition | ISSN: 2470-1076
- Journal Of Forensic Legal & Investigative Sciences | ISSN: 2473-733X
- Journal Of Gastroenterology & Hepatology Research | ISSN: 2574-2566
- Journal Of Genetics & Genomic Sciences | ISSN: 2574-2485
- Journal Of Gerontology & Geriatric Medicine | ISSN: 2381-8662
- Journal Of Hematology Blood Transfusion & Disorders | ISSN: 2572-2999
- Journal Of Hospice & Palliative Medical Care
- Journal Of Human Endocrinology | ISSN: 2572-9640
- Journal Of Infectious & Non Infectious Diseases | ISSN: 2381-8654
- Journal Of Internal Medicine & Primary Healthcare | ISSN: 2574-2493
- Journal Of Light & Laser Current Trends
- Journal Of Medicine Study & Research | ISSN: 2639-5657
- Journal Of Modern Chemical Sciences
- Journal Of Nanotechnology Nanomedicine & Nanobiotechnology | ISSN: 2381-2044
- Journal Of Neonatology & Clinical Pediatrics | ISSN: 2378-878X
- Journal Of Nephrology & Renal Therapy | ISSN: 2473-7313
- Journal Of Non Invasive Vascular Investigation | ISSN: 2572-7400
- Journal Of Nuclear Medicine Radiology & Radiation Therapy | ISSN: 2572-7419
- Journal Of Obesity & Weight Loss | ISSN: 2473-7372
- Journal Of Ophthalmology & Clinical Research | ISSN: 2378-8887
- Journal Of Orthopedic Research & Physiotherapy | ISSN: 2381-2052
- Journal Of Otolaryngology Head & Neck Surgery | ISSN: 2573-010X
- Journal Of Pathology Clinical & Medical Research
- Journal Of Pharmacology Pharmaceutics & Pharmacovigilance | ISSN: 2639-5649
- Journal Of Physical Medicine Rehabilitation & Disabilities | ISSN: 2381-8670
- Journal Of Plant Science Current Research | ISSN: 2639-3743
- Journal Of Practical & Professional Nursing | ISSN: 2639-5681
- Journal Of Protein Research & Bioinformatics
- Journal Of Psychiatry Depression & Anxiety | ISSN: 2573-0150
- Journal Of Pulmonary Medicine & Respiratory Research | ISSN: 2573-0177
- Journal Of Reproductive Medicine Gynaecology & Obstetrics | ISSN: 2574-2574
- Journal Of Stem Cells Research Development & Therapy | ISSN: 2381-2060
- Journal Of Surgery Current Trends & Innovations | ISSN: 2578-7284
- Journal Of Toxicology Current Research | ISSN: 2639-3735
- Journal Of Translational Science And Research
- Journal Of Vaccines Research & Vaccination | ISSN: 2573-0193
- Journal Of Virology & Antivirals
- Sports Medicine And Injury Care Journal | ISSN: 2689-8829
- Trends In Anatomy & Physiology | ISSN: 2640-7752

Submit Your Manuscript: <https://www.heraldopenaccess.us/submit-manuscript>