

## Epidemio-Clinical, Therapeutic and Evolving Aspects of Tropical Endemic Limboconjunctivitis in Children in the Ophthalmology Department of the Bouake University Hospital Center

Diomandé GF<sup>1\*</sup>, Bile PFEK<sup>1</sup>, Koffi FH<sup>1</sup>, Konan MP<sup>2</sup>, Kouaibi T<sup>3</sup>, Goule AM<sup>1</sup>, Assua KE<sup>1</sup>, Diabaté Z<sup>1</sup>, Gode L<sup>1</sup>, Babayeju RLO<sup>1</sup>, Ouattara Y<sup>1</sup> and Diomandé IA<sup>1</sup>

<sup>1</sup>Department of Ophthalmology, Center Hospital University of Bouaké, Côte d'Ivoire

<sup>2</sup>Department of Ophthalmology, Center Hospital University of Cocody, Côte d'Ivoire

<sup>3</sup>Department of Ophthalmology, Center Hospital University of Treicville, Côte d'Ivoire

### Abstract

**Introduction:** Tropical Endemic Limboconjunctivitis (TELC) or vernal kerato-conjunctivitis in temperate countries is a very recurrent chronic disease frequently affecting children aged 0 to 15 years in tropical areas and inter-tropical.

**Materials and methods:** We set out to conduct a descriptive retrospective cross-sectional study over 1 year in the ophthalmology department of Bouaké's university hospital center.

**Results:** The hospital frequency was 34.18%. The mean age of our patients was 6.14 years with a predominance of men (59.70%). Ocular pruritus (95.38%) was the first reason for consultation. Patients with 2 annual seizures were the most numerous with 48.94%. Limbit (65%) were adnexal lesions. Superficial punctate keratitis was the most observed lesion of the anterior segment with 80%. Stage II of Diallo's classification with 66.53% was the most observed in our patients. The antihistamine was the most prescribed specific medical

treatment with 56.15%. The post-treatment course was favorable in the majority of our patients with 82%.

**Analysis and discussion:** Very recurrent allergic pathology of chronic course occurring in children. It is characterized by various damages to the structures of the ocular surface. Its essentially medical treatment is long and restrictive. Its course is generally favorable but it can affect the quality of the child's eyesight if the treatment is delayed.

**Conclusion:** Tropical endemic limboconjunctivitis remains an endemic and recurrent disease in children in the tropics and inter-tropics. Its clinical diagnosis is easy but its medical care remains complex.

**Keywords:** Antihistamine; Benign; Child; Endemic; Limboconjunctivitis

### Introduction

Tropical Endemic Limboconjunctivitis (TELC) vernal keratoconjunctivitis in temperate countries is a sub-acute or chronic inflammation of the limbs and conjunctiva secondary to exposure of the eye to an allergenic or irritant agent [1].

It is a common condition in children between 4 and 7 years of age in tropical and inter-tropical areas because it accounts for 0.1 to 0.5% of eye problems in children [2]. It is classified into 4 evolutionary stages according to Diallo and presents 3 clinical forms, namely the palpebral, bulbar and mixed form [3]. It is usually mild but can sometimes be complicated by severe corneal damage due to scratching lesions that may progress to blindness [4]. The management of this condition is long and restrictive, so the success of the treatment depends on close collaboration between the doctor and the family or the patient, the only guarantee of good therapeutic compliance. The aim of this study was to contribute to a better knowledge of TELC in order to improve its management.

### Materials and Methods

This descriptive retrospective cross-sectional study was carried out in the ophthalmology department of the university hospital center of Bouaké from January 01, 2020 to December 31, 2020 (1 year).

It enabled us to identify 201 patients aged 0 to 15 years with signs of Tropical endemic limboconjunctivitis who had or have not received treatment.

A case of TELC was defined by the simultaneous existence of the following three criteria from Diallo's work [3] in one patient.

**Criterion 1:** associates conjunctival hyperemia and superficial punctate keratitis.

**Criterion 2:** associates at least one of the following three signs, a limbit and / or grains of trantas and or follicles or papillae in cobblestones.

**Criterion3:** ocular itch.

**\*Corresponding author:** Diomandé GF, Center Hospital University of Bouaké, Côte d'Ivoire, Tel: +225 46804233/03123230; E-mail: diomandgosse@gmail.com

**Citation:** Diomandé GF, Bile PFEK, Koffi FH, Konan MP, Kouaibi T, et al. (2021) Epidemio-Clinical, Therapeutic and Evolving Aspects of Tropical Endemic Limboconjunctivitis in Children in the Ophthalmology Department of the Bouake University Hospital Center. J Ophthalmic Clin Res 8: 088.

**Received:** September 23, 2021; **Accepted:** October 01, 2021; **Published:** October 08, 2021

**Copyright:** © 2021 Diomandé GF, et al. This is an open-access article distributed under the terms of the Creative Commons Attribution License, which permits unrestricted use, distribution, and reproduction in any medium, provided the original author and source are credited.

Any child, who consulted during the study period for signs of eye allergy, but in whom these criteria could not be found simultaneously, was excluded from the study.

The analyzed parameters were epidemiological (disease frequency, gender, age), Clinical (reason for consultation, clinical signs, time elapsed before the first consultation, number of seizures during the year, family history, visual acuity, slit lamp examination, stage according to Diallo's classification), therapeutic (specific treatment and adjuvant treatment) progressive (without treatment and under treatment).

After reviewing the files, the figures were produced in Excel 2007, the tables and data entry in World 2007 and the data analysis were carried out using the EPI info software version 7.0.

## Results

### Epidemiology

Out of a total of 588 files of children aged 0 to 15 years analyzed, 201 had Tropical endemic limboconjunctivitis corresponding to a relative frequency of 34.18% (Table 1). The mean age of the patients was 6.14 years with extremes of 6 months and 15 years. The majority of our patients with TELC, i.e. 59.70% (120/201), were male with a sex ratio of 1.40 (Table 2).

Pathologies	Number of children	Frequency (%)
TELC	201	34.18
Conjunctivitis	117	19.90
Refractive errors	98	16.67
Eye trauma	77	13.09
Tumors	39	6.64
Blepharitis	25	4.25
Keratitis	22	3.74
Others	9	1.53
Total	588	100

**Table 1:** Frequencies of eye pathologies in children in our department.

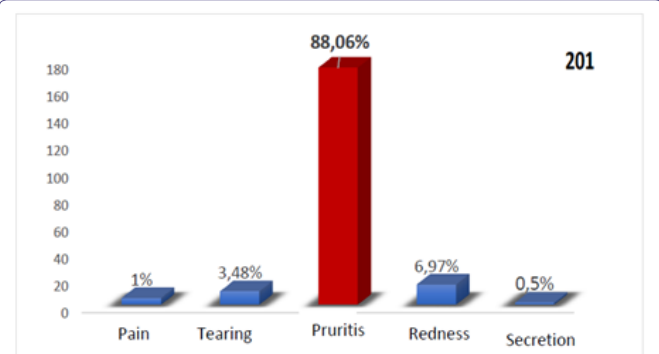
TELC		
Age (year)	Gender	
	Male	Female
0-4	36	24
5-10	65	41
11-15	19	16
Total	120	81

**Table 2:** Distribution of patients with TELC by age and gender.

### Clinical

Eye itching was the main reason for consultation with 88.06% (262/297 patients) (Figure 1). The majority of our patients had consulted before 1 month after the onset of the first symptoms, i.e. 74.63% (150/201). The patients who presented 2 seizures during the year were the most numerous with 48.94% (99/201 patients). Familial atopy was at the forefront of the family history with 40.5% (81/201 patients). Our patients in whom visual acuity could be measured had visual acuity > 3/10 in the majority of cases, i.e. 72.72% (96/132 eyes) in the right eye and 63.63% (83/130 eyes) in the left eye (Table 3). Limbit represented the most frequent adnexal involvement with 65%

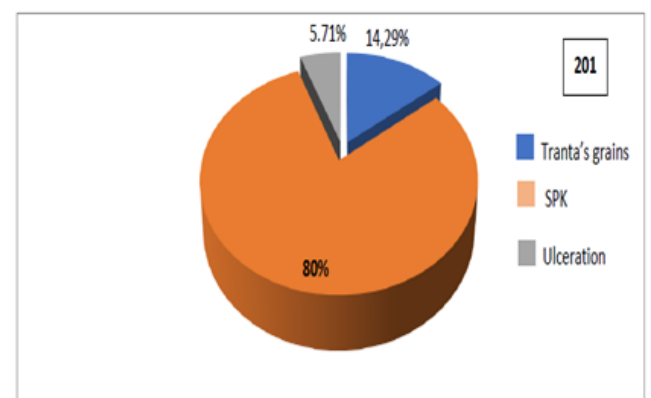
(70/201 patients). Superficial punctate keratitis was the most observed anterior segment lesion with 80% (46/58 patients) (Figure 2). Most of our patients had been received at stage II of Diallo's classification with 66.53% (134/201 patients) (Figure 3).



**Figure 1:** Repartition of patients according to the reason for consultation.

	Right eye		Left eye	
	Numbers	Percentage	Numbers	Percentage
AVL	(eyes)	(%)	(eyes)	(%)
≤1/20	10	9.09	16	14.54
[1/20-3/20]	20	18.18	24	21.81
> 3/10	80	72.72	70	63.63
Total	132	100	110	100

**Table 3:** Repartition of patients according to visual acuity.



**Figure 2:** Repartition of patients according to lesions observed in the anterior segment.

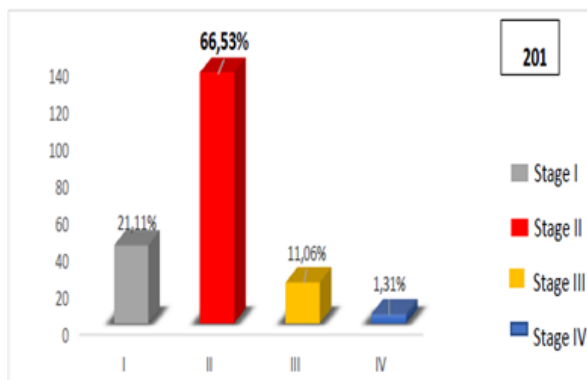
### Treatment

The antihistamine was the most prescribed specific medical treatment with 56.15 % (177/315 patients) followed by anti-biocorticoids 42.46% (134/315).

The post-treatment course was favorable in the majority of our patients with 82%. Fibro vascular veil was the most common complication in our patients who consulted late with 44.82% (Table 4) (Figure 4).

### Discussion

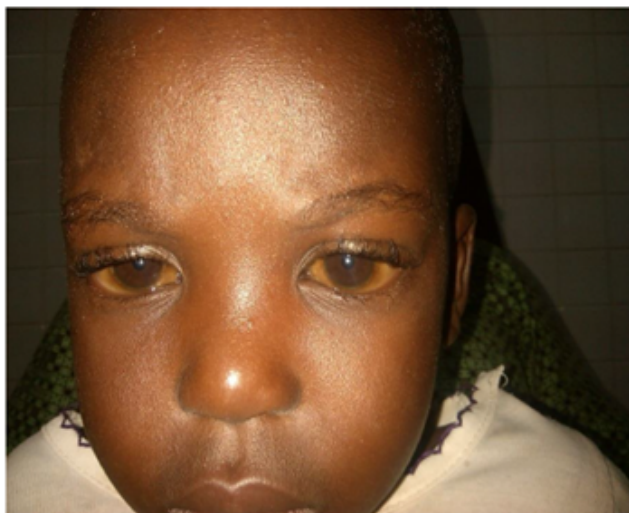Tropical Endemic Limboconjunctivitis (TELC) or vernal kerato-conjunctivitis accounts for 0.1 to 0.5% of eye problems in children between 0 and 15 years [2]. The relative frequency of TELC in our



**Figure 3:** Repartition of patients according to DIALLO's classification.

Complications	Number of Patients	Percentage
	Patients	%
Fibro vascular veil	13	44.82
Corneal panus	10	34.48
Corneal dystrophy	4	13.79
Keratoconus	2	6.91
Total	29	100

**Table 4:** repartition of patients who consulted late according to complications.



**Figure 4:** A 6-year-old girl with bilateral TELC seen during our consultation at the ophthalmology department of the UNIVERSITY HOOSPITAL CENTER in Bouake on 02-20-2020.

study was 34.18% indicating its resurgence in recent years due to the heavy pollution of urban areas.

Throughout the literature, the frequencies of TELC vary according to the regions concerned. However, our results are superimposable of those of Chenge [5] in Cameroon (32.9%) and Koki [6] in Congo (31.55%) but by far differ from those of Resnikoff [7] in Chad and Bremond [8] in France found respective prevalence of TELC of 5% and 0.032% in their patients. Although, allergic kerato-conjunctivitis is a cosmopolitan affection it is particularly prevalent in sub-Saharan Africa, Asia, the Mediterranean region and Latin America due to their

hot climate and moist favorable to the expansion of allergens [9]. All these areas are characterized by more sunlight; increased ultraviolet rays and the permanent presence of dusty air are all factors in the occurrence of conjunctivitis allergic and particularly in that of TELC [7]. The average age of our patients was 6.14 years with extremes of 6 months and 15 years. Our results are in accordance with those of some authors who in their respective works noted similar averages of age; these are the cases of Banla [10] in Togo (6.5 years) and Lazreg [11] in Algeria (6, 5 years  $\pm$  3.4). The immaturity of the immune system of children from 0 to 15 years old described by Bloch-Michel [12] would be at the origin of the early onset of immediate hypersensitivity to dust and photosensitivity in the latter, thus promoting the occurrence of TELC.

Male subjects were in the majority (59.71%) with a sex ratio of 1.40. This male predominance of limbo-conjunctivitis was also observed in the work of Al-Akily [13] in Yemen and Banla [10] in Togo with respective sex ratios of 3 and 1.6. This clear male predominance of TELC could be linked to the greater freedom granted to little boys resulting in their more frequent contact with dust and pollen grains during play compared to the young girl.

Ocular pruritus was the most frequent reason for consultation with (88.06%).

The presence of ocular pruritus as the most common functional sign in our patients. Koki [6] and Saboo [14] in their respective work carried out in Cameroon and India on allergic kerato-conjunctivitis, they noted the constant presence of ocular pruritus in their patients at frequencies of 60.90% and 88%. The presence of ocular pruritus as the main clinical manifestation of allergic conditions has its source in the pathogenesis of this disease.

Non-specific conjunctival causing intense pruritus [15]. Our patients had made their first consultation in the majority of cases before 1 month after the onset of the first symptoms (74.63%).

The parents' rapid reaction to TELC is due on the one hand to the embarrassing manifestations of this condition with sometimes a change in the color of the eyes and on the other hand their concern for the visual functional prognosis of their offspring.

The period from December to February recorded the highest number of consultations in the year at respective frequencies of 15%, 17.50% with a peak in December (32.34%). The resurgence of TELC during the dry season is found in many works in Africa. Thus Resnikoff [7] and Nidain [16] noted respectively in Chad and Togo peaks of occurrence of TELC March (47.6%) and in April (95.08%) corresponding to dry seasons in these different areas. The frequent occurrence of this condition during the dry seasons of the year would be consistent with the pathogenesis of TELC involving various factors such as more intense solar radiation, very dusty air and especially the expansion of pollen grains. In our series, patients who presented 2 annual seizures came to the fore with 48.94%. The same observation was made by BANLA [10] who noted recurrence in 77.8% of cases, when allergological management was late. These recurrences are believed to be due in part to difficulties in isolating the causative allergen, so symptoms reappear as soon as the patient comes into contact with it again. The recurrent nature of TELC is at the origin of the chronicity of this condition which generates corneal complications due to scratching lesions. This permanent corneal damage could put into stake the visual functional prognosis making all the seriousness of this affection.

Familial atopy was the most common family medical history in 40.5% of cases, followed by asthma (27%) and allergic rhinitis (25%). LAZREG [11] in its study carried out in Algeria on the treatment of perennial allergic conjunctivitis noted the predominance of allergic rhinitis (37%) and asthmatic disease (16%).

The association of other extra ocular allergic manifestations is thought to be due both to the involvement of immunoglobulin dependent of mechanisms and to genetic factors involved in the genesis of vernal kerato-conjunctivitis or Tropical endemic limboconjunctivitis [17]. Most of our patients had better visual acuity > 3/10 with 72.72% in the right eye and 63.63% in the left eye.

Our results are close to those of Chenge [5] in Cameroun and Saboo [14] in India who found good visual acuity in their patients in the respective proportions of 81% and 100%.

This reflects the early management of a large number of patients before the onset of complications, but it also highlights the benign nature of this condition. However, blindness was observed in 9.09% in the right eye and 14.54% in the left eye of our patients whose management was late. Chenge [5] made the same observation in these patients who presented blindness in 10.53% of cases. The functional loss of the eye during this condition is thought to be due to the occurrence of corneal complications linked to late consultations due to lack of financial means as well as to the scarcity of specialized structures.

The limbus was the most affected adnexal structure with 65%. Our results can be compared to those of Saboo [14] in India and Al-Akily [13] in Yemen, who found 73% and 50% limbic involvement, respectively, in their studies on vernal kerato-conjunctivitis. Chenge [5] in Cameroon and Ukponmwa [18] in Nigeria also noted damage to the corneal limbus in all of their patients with TELC. These data would testify to the importance of this sign in the TELC giving it its name in Africa. This manifestation is also sometimes a source of complications related to a corneal invasion of reactive neovessels causing blindness by the loss of corneal transparency. Superficial punctate keratitis was the lesion of the anterior segment the most found with 80%. Corneal involvement in endemic limbo-conjunctivitis in the tropics or vernal kerato-conjunctivitis in temperate zones was also found in studies by Bremond [8] in Europe and Khan [19] in Pakistan, which found respectively 31, 7%, and 49% of corneal lesions cases. The corneal lesions observed during this affection are the resultant of late consultations in developing countries, frequent recurrence of the disease and its evolution towards chronicity. Patients admitted to stage II of Diallo's classification were in the majority with 66.53%. Some African authors would confirm that stage II of TELC constitutes the diagnostic stage of the disease in the tropics, thus N'diaye [20] in Senegal, Banla [10] in Togo respectively noted frequencies of 51.7% and 50% of patients seen in stage II.

All these results are linked by the expressive nature of the symptoms at this stage of the disease, thus constituting a real visual discomfort, forcing patients to consult a doctor. However, Koki [6] in Cameroon and Ayena [21] in Togo noted a clear predominance of patients consulting with stage I of the disease in proportions of 55.25% and 64.8%. This variability of the stage at which the patient is admitted for consultation would be related to the susceptibility of the patients and also the atopic history sometimes worsening the clinical table [17]. Antihistamines were the most specific treatment prescribed in our daily practices with 56, 62% followed by antibiotic -corticosteroids (42.46%). This fact has been reported in various works.

In the studies carried out in Algeria by Lazreg [11], and in Senegal by N'doye [20], we noted the massive use of antihistamine. Although the antihistamine is the treatment of choice, the antibiotic corticosteroid also plays an important role in the treatment of TELC because it makes it possible to fight effectively against inflammation and prevent or treat super infection. The post-treatment course was favorable in 82.08% of our patients with improvement of symptoms. The same observation has been made by several authors, such as Al-Akily [13] in Iran and N'doye [20] in Senegal, who respectively found 84.3% and 87.60% recovery after well-conducted medical treatment. The favorable outcome of limbo-conjunctivitis under drug treatment could be explained on the one hand by the benign nature of this condition and on the other hand by the effectiveness of the combination of antihistamines and antibiotic corticosteroids in the management of endemic limbo-conjunctivitis in the tropics. However, 6.96% of patients presented complications, the most frequent of which was represented by the fibro vascular veil with 35.71%. Corneal involvement has been found as a major complication of keratoconjunctivitis in the world literature. For example, Khan [18] in Pakistan and Tabbara [4] in Saudi Arabia found corneal complications in patients with vernal keratoconjunctivitis at frequencies of 49% and 17.3%, respectively. These complications would result from late consultations linked to the scarcity of specialty services, the insufficiency of specialists, lack of financial means and above all, treatment non-compliance.

## Conclusion

Tropical endemic limboconjunctivitis is a chronic relapsing allergic disease seen in the majority of cases in children. It is a generally benign condition characterized by the maintenance of visual acuity and the main manifestation of which remains ocular pruritus. Its evolution is most often favorable but can sometimes be complicated by corneal lesions when the medical treatment is late or poorly conducted. This corneal damage is the whole issue of this condition because it can affect the visual functional prognosis. Hence the value of early diagnosis and rapid medical care of children is the only guarantee of good progress.

## References

1. Creuzot-Garcher C (2007) Different clinical forms of conjunctival allergy. *J Fr Ophthalmol* 30: 288-291.
2. Rayees AS, Mufti A (2016) Vernal Kerato-conjunctivitis in Kashmir: A temperate zone. *Int Ophthalmol* 1: 1-5.
3. Diallo J-S (1976) Tropical endemic limboconjunctivitis. *Rev int trachoma* 4: 71-80.
4. Tabbara KF (1999) Ocular complications of vernal kerato- conjunctivitis. *Can J Ophthalmol* 34: 88-92.
5. Chenge OEA, Bella AL, Owono D, Mbome S, Ebana MC (2009) Ocular pathology in children aged six to 15: hospital study in Yaoundé Heath copy book. 19: 61-66.
6. Koki G, Eballe AO, Epee E, Njapdunke SBN, Wadjiri YS, et al. (2011) Tropical endemic Limboconjunctivitis in northern Cameroon. *J Froptalmol* 34: 113-117.
7. Resnikoff S, Cornand G (1988) Tropical limbo conjunctivitis. *Rev int trach path Ocul Sub Trop* 65: 21-72.
8. Bremond-Gignac D, Donadieu J, Leonardi A, Pouliquen P, Doan S, et al., (2008) Prevalence of vernal keratoconjunctivitis: a rare disease? *Br J Ophthalmol* 92: 1097-1102.
9. Tuft SJ, Cree IA, Woods M, Yorston D (1998) Limbal Vernal Keratoconjunctivitis in the Tropics. *Ophthalmology* 105: 1489-1493.



10. Banla M, Maneh N, Vonor B, Nonan K, Agbaa, et al. (2013) Tropical endemic limboconjunctivitis (TELC) and management allergological: Preliminary study in Togolese children. *Fr Ophthalmol* 36: 677-682.
11. Lazreg S, Colin J, Renault D, Hartani D (2008) Intra-annual and seasonal allergic conjunctivitis treatment: comparison of two therapeutic protocols. *J Fr Ophtalmol* 10: 963-967.
12. Bloch-Michel E, Dry J, Herman D (1977) Spring conjunctivitis. *Rev Fr allerge* 17: 57-64.
13. Al-Akily SA, Bamashmus MA (2011) Ocular complications of severe vernal keratoconjunctivitis (VKC) in Yemen. *Sau J Ophthalmol* 25: 291-294.
14. Saboo US, Jain M, Reddy JC, Sangwan VS (2013) Demographic and clinical profile of vernal keratoconjunctivitis at a tertiary eye care .center in India. *Indian J Ophthalmol* 61: 486-489.
15. Chiambaretta F, Lazreg S (2015) Vernal keratoconjunctivitis. SFO report, Paris, France.
16. Nidain M, Kassoula N, Ayena K, Kokou V, Banla M, et al. (2015) Tropical endemic Limbo-Conjunctivitis and seasonal influence in Togo. *Research* 6: 1293-1302.
17. Jun J, Bielory L, Raizman MB (2008) Vernal Conjunctivitis. *Immunol Allergy Clin N Am* 28: 59-82.
18. Ukponmwa CU (2003) Vernal kerato-conjunctivitis in Nigerians: 109 consecutive cases. *Trop Doct* 33: 242-245.
19. Khan MD, Kundi N, Saeed N, Gulab A, Nazeer AF (1988) Incidence of Keratoconus in Spring Catarrh. *Br J Ophthalmol* 72: 41-43.
20. Roth N, Hemo N, Khouma W, Ba H, Sow H, et al. (2012) Intratarsal injection of triamcinolone acetonide in the treatment of severe forms of chronic tropical endemic limbo conjunctivitis (TELC). *J-Fr* 35: 266-272.
21. Ayena KD, Banla M, Agbo ADR, Gnent OB, Balo K (2008) Epidemiological and clinical aspect of TELC in rural areas in Togo. *Med BLACK AFRICA* 55: 319-324.



- Advances In Industrial Biotechnology | ISSN: 2639-5665
- Advances In Microbiology Research | ISSN: 2689-694X
- Archives Of Surgery And Surgical Education | ISSN: 2689-3126
- Archives Of Urology
- Archives Of Zoological Studies | ISSN: 2640-7779
- Current Trends Medical And Biological Engineering
- International Journal Of Case Reports And Therapeutic Studies | ISSN: 2689-310X
- Journal Of Addiction & Addictive Disorders | ISSN: 2578-7276
- Journal Of Agronomy & Agricultural Science | ISSN: 2689-8292
- Journal Of AIDS Clinical Research & STDs | ISSN: 2572-7370
- Journal Of Alcoholism Drug Abuse & Substance Dependence | ISSN: 2572-9594
- Journal Of Allergy Disorders & Therapy | ISSN: 2470-749X
- Journal Of Alternative Complementary & Integrative Medicine | ISSN: 2470-7562
- Journal Of Alzheimers & Neurodegenerative Diseases | ISSN: 2572-9608
- Journal Of Anesthesia & Clinical Care | ISSN: 2378-8879
- Journal Of Angiology & Vascular Surgery | ISSN: 2572-7397
- Journal Of Animal Research & Veterinary Science | ISSN: 2639-3751
- Journal Of Aquaculture & Fisheries | ISSN: 2576-5523
- Journal Of Atmospheric & Earth Sciences | ISSN: 2689-8780
- Journal Of Biotech Research & Biochemistry
- Journal Of Brain & Neuroscience Research
- Journal Of Cancer Biology & Treatment | ISSN: 2470-7546
- Journal Of Cardiology Study & Research | ISSN: 2640-768X
- Journal Of Cell Biology & Cell Metabolism | ISSN: 2381-1943
- Journal Of Clinical Dermatology & Therapy | ISSN: 2378-8771
- Journal Of Clinical Immunology & Immunotherapy | ISSN: 2378-8844
- Journal Of Clinical Studies & Medical Case Reports | ISSN: 2378-8801
- Journal Of Community Medicine & Public Health Care | ISSN: 2381-1978
- Journal Of Cytology & Tissue Biology | ISSN: 2378-9107
- Journal Of Dairy Research & Technology | ISSN: 2688-9315
- Journal Of Dentistry Oral Health & Cosmesis | ISSN: 2473-6783
- Journal Of Diabetes & Metabolic Disorders | ISSN: 2381-201X
- Journal Of Emergency Medicine Trauma & Surgical Care | ISSN: 2378-8798
- Journal Of Environmental Science Current Research | ISSN: 2643-5020
- Journal Of Food Science & Nutrition | ISSN: 2470-1076
- Journal Of Forensic Legal & Investigative Sciences | ISSN: 2473-733X
- Journal Of Gastroenterology & Hepatology Research | ISSN: 2574-2566
- Journal Of Genetics & Genomic Sciences | ISSN: 2574-2485
- Journal Of Gerontology & Geriatric Medicine | ISSN: 2381-8662
- Journal Of Hematology Blood Transfusion & Disorders | ISSN: 2572-2999
- Journal Of Hospice & Palliative Medical Care
- Journal Of Human Endocrinology | ISSN: 2572-9640
- Journal Of Infectious & Non Infectious Diseases | ISSN: 2381-8654
- Journal Of Internal Medicine & Primary Healthcare | ISSN: 2574-2493
- Journal Of Light & Laser Current Trends
- Journal Of Medicine Study & Research | ISSN: 2639-5657
- Journal Of Modern Chemical Sciences
- Journal Of Nanotechnology Nanomedicine & Nanobiotechnology | ISSN: 2381-2044
- Journal Of Neonatology & Clinical Pediatrics | ISSN: 2378-878X
- Journal Of Nephrology & Renal Therapy | ISSN: 2473-7313
- Journal Of Non Invasive Vascular Investigation | ISSN: 2572-7400
- Journal Of Nuclear Medicine Radiology & Radiation Therapy | ISSN: 2572-7419
- Journal Of Obesity & Weight Loss | ISSN: 2473-7372
- Journal Of Ophthalmology & Clinical Research | ISSN: 2378-8887
- Journal Of Orthopedic Research & Physiotherapy | ISSN: 2381-2052
- Journal Of Otolaryngology Head & Neck Surgery | ISSN: 2573-010X
- Journal Of Pathology Clinical & Medical Research
- Journal Of Pharmacology Pharmaceutics & Pharmacovigilance | ISSN: 2639-5649
- Journal Of Physical Medicine Rehabilitation & Disabilities | ISSN: 2381-8670
- Journal Of Plant Science Current Research | ISSN: 2639-3743
- Journal Of Practical & Professional Nursing | ISSN: 2639-5681
- Journal Of Protein Research & Bioinformatics
- Journal Of Psychiatry Depression & Anxiety | ISSN: 2573-0150
- Journal Of Pulmonary Medicine & Respiratory Research | ISSN: 2573-0177
- Journal Of Reproductive Medicine Gynaecology & Obstetrics | ISSN: 2574-2574
- Journal Of Stem Cells Research Development & Therapy | ISSN: 2381-2060
- Journal Of Surgery Current Trends & Innovations | ISSN: 2578-7284
- Journal Of Toxicology Current Research | ISSN: 2639-3735
- Journal Of Translational Science And Research
- Journal Of Vaccines Research & Vaccination | ISSN: 2573-0193
- Journal Of Virology & Antivirals
- Sports Medicine And Injury Care Journal | ISSN: 2689-8829
- Trends In Anatomy & Physiology | ISSN: 2640-7752

Submit Your Manuscript: <https://www.heraldopenaccess.us/submit-manuscript>