

Case Report

Acute Parotitis in a Preterm Infant with Methicillin Sensitive *Staphylococci*: A Case Review

Des Bharti^{*}, Darshan Shah and Shawn Hollinger

Department of Pediatrics, Quillen College of Medicine - East Tennessee State University, Johnson City, USA

Abstract

Acute parotitis is uncommon in the neonatal period. It can present with erythema and swelling over the parotid region or a purulent drainage inside the mouth. Early clinical diagnosis with support of sonography may avoid possible need for expensive MRI or CT scan studies. Culture of the drainage material and blood are crucial for bacterial identification and successful treatment. The authors describe a case of a preterm infant diagnosed with acute parotitis with MSSA sepsis.

Keywords: Acute parotitis; Preterm infant

Abbreviations

MSSA: Methicillin Sensitive *Staphylococci*

MRI: Magnetic Resonance Imaging

CT Scan: Computerized Tomography Scan

CPAP: Continuous Positive Airway Pressure

CRP: C Reactive Proteins

Case report

A 970 g, 30 weeks and 1 day gestation, small for gestational age, female infant was born by cesarean section for worsening pre-eclampsia. Mom is 32 years old, healthy, gravida 3, para 1010.

***Corresponding author:** Des Bharti, Department of Pediatrics, Quillen College of Medicine - East Tennessee State University, Johnson City, USA, Tel: + 423 4396222; E-mail: BHARTI@mail.etsu.edu

Citation: Bharti D, Shah D, Hollinger S (2018) Acute Parotitis in a Preterm Infant with Methicillin Sensitive *Staphylococci*: A Case Review. J Neonatol Clin Pediatr 5: 023.

Received: May 25, 2018; **Accepted:** July 23, 2018; **Published:** August 07, 2018

Copyright: © 2018 Bharti D, et al., This is an open-access article distributed under the terms of the Creative Commons Attribution License, which permits unrestricted use, distribution, and reproduction in any medium, provided the original author and source are credited.

Pregnancy was complicated by intrauterine growth retardation, gestational hypertension and worsening pre-eclampsia. The Infant was born with Apgar scores of 4 at 1 and 7 at 5 minutes.

She was noted to have respiratory distress syndrome. She was given a dose of surfactant in the delivery room followed by continuous positive airway pressure for 7 days. Feedings were introduced on the 3rd day of life and were gradually advanced as per feeding protocol. She required supplemental hype alimentation for 22 days of life. Total IgM was less than 20, urine for cytomegalovirus was reported negative.

On day 29 of life, infant was noted to have erythema and swelling above and below the right ear. No purulent discharge was noted inside the mouth. Complete blood count showed white blood count 29,100 with 24% bands and platelet count of 393,000/uL. CRP was 155.9 mg per L. CRP returned to normal range on day 5 of antibiotic therapy. Serum electrolytes were in the normal range.

Figure 1 is a grayscale ultrasound study in the right upper neck in the region of right parotid gland. Figure 2 is a doppler ultrasound in the right upper neck in the region of right parotid gland. Both studies indicate heterogeneous, hypoechoic, hypervascular mass in the right upper neck in the region of right parotid gland. No fluid collection or abscess was identified. Comparison images were obtained of the left neck demonstrating a normal-appearing parotid gland at the same site.

Blood culture was reported positive for MSSA. The infant initially received vancomycin for 2 days and after getting sensitivity report, she was switched to nafcillin for an additional 8 days. The erythema and swelling resolved in 5 days.

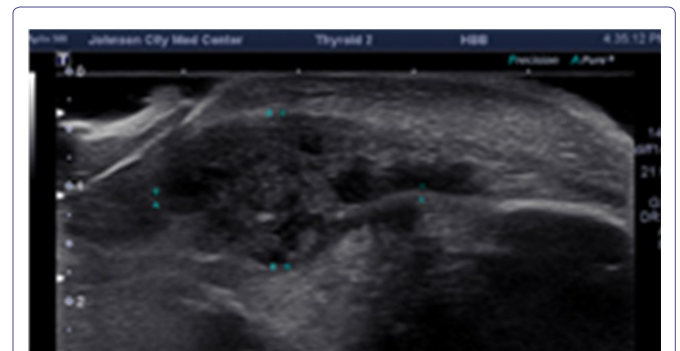


Figure 1: Grayscale sonographic image of the right parotid region.

No fluid collection or abscess is identified. There is a heterogeneous and hypoechoic mass in the right parotid region.

Discussion

Preterm newborn infants are relatively immune compromised [1,2]. They have lower levels of immunoglobulins and neutrophils in preterm newborn infants are deficient in chemotactic activity and bacterial killing capacity. Preterm infants have immature neonatal skin barrier. A significant number of these babies get resuscitated and may

require invasive therapeutic interventions that make them potentially at higher risk for infection. Skin and mucous membranes are porous in premature infants. We reported an infant with zipper associated skin injury that led to a skin abscess requiring incision and drainage [3].

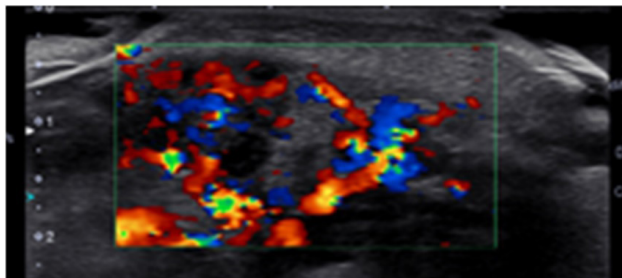


Figure 2: Color doppler sonographic image of the right parotid region.

A hypervascular mass in the right parotid region.

Inflammation of the parotid gland may be related to direct introduction of infection through Stenson's duct or by hematogenous spread. The increased risk of parotitis among preterm infants has been attributed to their increased risk of dehydration, which may reduce salivary secretion. Our patient maintained serum electrolytes in the normal range and the urine output stayed between 3-5 ml/kg/hour. MSSA was reported positive from blood culture. *Staphylococcus* is the most common etiology for late onset neonatal sepsis. Late onset of neonatal sepsis can be seen in newborn infants between days 5 to day 90 of life. 73% are caused by gram-positive organisms, with Coagulase-Negative *Staphylococci* accounting for 55% of all infections. Rate of infection was inversely related to birth weight and gestational age [4]. It is reported in approximately 10% of all neonates and more than 25% of very low birth weight infants. The common organisms reported are Coagulase Negative *Staphylococci*, *Staphylococcus aureus*, *Enterobacter*, *Candida* and Group B *Streptococcus* [5]. Risk for sepsis in infant less than 1000 g is 26 per thousand. There are several potential risk factors for sepsis in preterm infants that include maternal group B strep colonization, premature rupture of membranes, maternal chorio-amnionitis, maternal UTI, poor prenatal care, African American mothers, low socioeconomic status, difficult delivery, birth asphyxia, meconium staining and congenital abnormalities [6]. Mechanical ventilation, use of H2 receptor blockers and central venous catheters add to the potential risk factors for sepsis. Over 70% of late onset sepsis is attributed to Coagulase Negative *Staphylococcus* and *Staphylococcus aureus*.

CRP is a simple and convenient nonspecific marker utilized for suspected cases of sepsis. The sensitivity and specificity of CRP on Day 1 is 62% and 87.7% increasing up to 70.2% and 97% on Day 2 of life [7]. Total immature to total neutrophil count ratio over 0.3 is seen in 85% of infant's with sepsis. Serial CRP levels and serial assessment of immature to total neutrophil counts ratio provide the best negative predictive value for neonatal sepsis. In our index patient, CRP was initially elevated and it returned to a normal range on day 5 of antibiotic therapy. Serum electrolytes were reported in the normal range at the time the clinical diagnosis was made based on erythema over the parotid region. There was no clinical evidence of dehydration. Serum alpha amylase was not checked in this study.

Baker and associates reported group B strep cellulitis-adenitis syndrome in infants between 2 to 10 weeks of age that presented with the abrupt onset of fever with associated poor feeding and irritability [8]. They reported cellulitis predominantly in submandibular region. Among recent interventions to prevent neonatal sepsis, the use of fluconazole prophylaxis in very low birth weight infants is the only intervention that has shown repeated efficacy in multiple trials [9].

The diagnosis of parotitis is essentially clinical. It is important to rule out cutaneous cellulitis, abscess, lipoma, subcutaneous fat necrosis and a swelling due to blocked Stenson's duct. Enlargement of the parotid gland is uncommon in the neonatal period. It could potentially be associated with hemangioma, lymphangioma, and tumors. Rarely, parotid swelling may be associated with autoimmune disorders including Sjogren syndrome. Mumps parotitis or parotitis associated with tuberculosis or human immunodeficiency virus illness may be seen in at risk population but it is unlikely to be seen in preterm infants. Hematogenous spread to the parotid gland, or ascending infection from the mouth through Stenson's duct, has been implicated in the development of parotitis. Malnutrition and dehydration are potentially risk factors for salivary stasis leading to bacterial contamination from the oral cavity.

Our index patient had multiple risk factors associated with the development of acute parotitis. She weighed less than 1000 g, was extremely premature, required respiratory support, and required a central venous catheter. Appropriate fluid management and electrolyte balance was provided throughout the hospital course. The diagnosis was made clinically and confirmed with ultrasound of the parotid region. CT or MRI was not needed in this case but should be considered when a diagnosis cannot be made by ultrasound. The infant had resolution of erythema within 48 hours. She required ten days of intravenous antibiotic. Otolaryngologic exam and examination of the mouth was unremarkable, there was no evidence of abscess based on clinical assessment or ultrasound studies.

Potentially, parotitis could be associated with morbidities and complications including respiratory compromise, pneumonitis, meningitis, thrombophlebitis of the central veins, cerebral venous emboli and infarcts, or osteomyelitis of the mandible, or temporomandibular joint. A minority of cases may require surgical treatment in the presence of an abscess. Other potential complications are facial palsy, mediastinitis, aspiration pneumonia, and salivary fistula. Prognosis with early diagnosis and appropriate antibiotic therapy based on the sensitivity of the organism is excellent. These infants need to be monitored closely for any associated or ensuing complications. A culture of the Stenson's duct drainage material and a blood culture should be done promptly. A consultation with an otolaryngologist or pediatric surgeon may be warranted.

Conclusion

Generally, it is easy to diagnose and treat acute parotitis with a course of antibiotics. It is important to rule out other etiologies for a swelling in the neck. Good oral hygiene and adequate hydration is advisable. Culture of the drainage material and blood is crucial for bacterial identification and successful treatment. Ultrasound studies are cheaper and convenient for a bed side diagnosis. Additional imaging with MRI or CT scan may be indicated when a diagnosis cannot be made conclusively with ultrasound studies.

References

1. Hill HR (1985) Host defenses in the neonate: Prospects for enhancement. *Semin Perinatol* 9: 2-11.
2. Hoffman David, Harris Mary C (1996) Diagnosis of neonatal sepsis, intensive care of the fetus and newborn. Pg no: 940-941.
3. Bharti Des, Gibson Jennifer (2018) Zipper induced skin injury leading to methicillin sensitive *Staphylococcus aureus* abscess in a premature infant. *Archives of Pediatrics and Neonatology* 1: 9-12.
4. Stoll BJ, Gordon T, Korones SB, Shankaran S, Tyson JE, et al. (1996) Late-onset sepsis in very low birth weight neonates: A report from the national institute of child health and human development neonatal research network. *J Pediatr* 129: 63-71.
5. Dong Y, Speer CP (2015) Late-onset neonatal sepsis: Recent developments. *Arch Dis Child Fetal Neonatal Ed* 100: 257-263.
6. Camacho-Gonzalez A, Spearman PW, Stoll BJ (2013) Neonatal infectious diseases: Evaluation of neonatal sepsis. *Pediatr Clin North Am* 60: 367-389.
7. Wagle S, Grauaug A, Kohan R, Evans SF (1994) C-reactive protein as a diagnostic tool of sepsis in very immature babies. *J Paediatr Child Health* 30: 40-44.
8. Baker CJ (1982) Group B streptococcal cellulitis-adenitis in infants. *Am J Dis Child* 136: 631-633.
9. Ericson JE, Benjamin DK Jr (2014) Fluconazole prophylaxis for prevention of invasive candidiasis in infants. *Curr Opin Pediatr* 26: 151-156.