

## Case Report

### Myeloid Sarcoma of Lacrimal Gland: A Case Report

Rutuja U Londhe, Sunil Y Swami\* and Arvind G Valand

Department of Pathology, SRTR Government Medical College, Ambajogai, Maharashtra, India

#### Abstract

Myeloid or granulocytic sarcoma is a tumor mass consisting of myeloid blasts, with or without maturation, occurring at extramedullary sites. It preferentially involves orbits and the subcutaneous tissue, but it may also occur in paranasal sinuses, lymph nodes, bone, spine, breasts, thyroid, salivary glands, small bowel, lungs or various pelvic organs. Its presentation in lacrimal gland is a very rare entity, where the tumor may occur prior to or after the diagnosis of underlying disease.

We report a case of myeloid sarcoma in a 10-year-old male who presented with protrusion of right eye and lid swelling progressively increasing in size for 1 month. Complete excision of the tumor and histopathologic diagnosis revealed evidence of Acute Myeloid Leukemia (AML). There were no other sites indicating any tumoral process; however, the bone marrow aspirate and the peripheral blood smear revealed an evidence of systemic disease. Myeloid sarcoma, although rare, should be considered as one of the differentials when a paediatric patient presents with proptosis or eyelid swelling.

**Keywords:** Granulocytic sarcoma; Lacrimal gland; Myeloid sarcoma; Proptosis

\*Corresponding author: Sunil Y Swami, Department of pathology, SRTR. Government Medical College, Ambajogai, Maharashtra, India, Tel: +91 9860006075; E-mail: drsys02@gmail.com

**Citation:** Londhe RU, Swami SY, Valand AG (2018) Myeloid Sarcoma of Lacrimal Gland: A Case Report. J J Cytol Tissue Biol 5: 018.

**Received:** July 23, 2018; **Accepted:** August 9, 2018; **Published:** August 24, 2018

**Copyright:** © 2018 Londhe RU, et al. This is an open-access article distributed under the terms of the Creative Commons Attribution License, which permits unrestricted use, distribution, and reproduction in any medium, provided the original author and source are credited.

#### Introduction

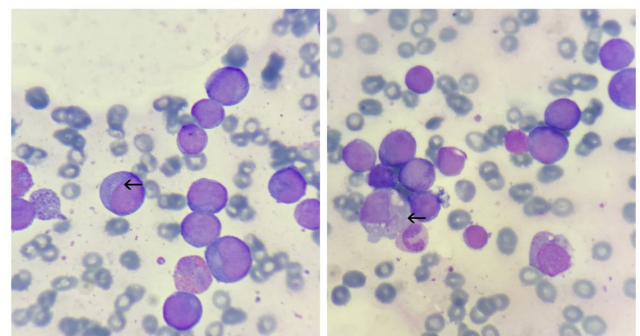
Myeloid sarcomas are rare complications of de novo AML [1]. The diagnosis of AML is based on finding greater than 30% myeloid blasts in the bone marrow. Myeloblasts have delicate nuclear chromatin, two to four nucleoli. The cytoplasm often contains fine, azurophilic, peroxidase positive granules often represented by auer rods. Evaluation of the peripheral smear is an invaluable tool in the diagnosis [2].

In AML, the immature blast cells are released in the blood circulation, reaching distant extramedullary sites including the lacrimal gland. Accumulation of these leukemic cells in the soft tissues is termed as Myeloid Sarcoma [MS]. MS has been reported in 2.5 to 8% of patients with AML [3].

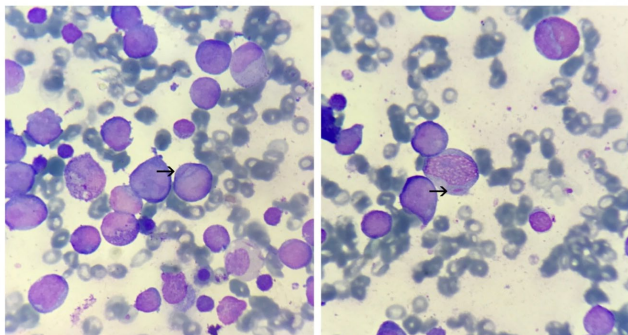
The occurrence of lacrimal gland myeloid sarcoma in children before the development of systemic leukemia, may frequently be confused with malignant tumors such as rhabdomyosarcoma, lymphoma and neuroblastoma. The accurate diagnosis of these cases can be challenging, particularly when there is no evidence of systemic disease and imaging features are not sufficiently specific to distinguish myeloid neoplasm from other tumors [4,5].

#### Case Report

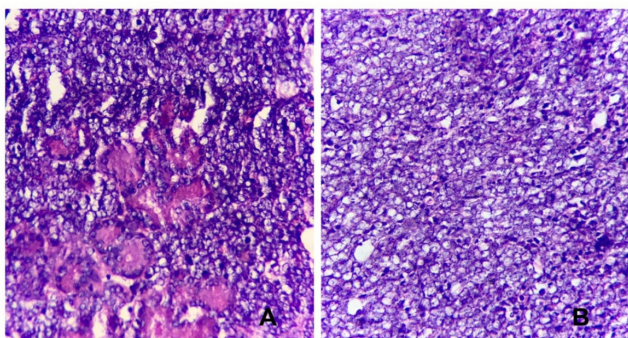
A 10-year-old male child came with complaints of protrusion of right eye and lid swelling for 1 month. Computed Tomography [CT] scan showed a well-defined, poorly marginated soft tissue mass involving the lacrimal gland, superior rectus and lateral rectus muscles of the right eye. Clinical diagnosis was an orbital pseudo tumour with a differential diagnosis of a lymphoma. The peripheral blood smear report was suggestive of an acute leukemia with the blast count of 40% (Figure 1). The bone marrow findings were suggestive of an acute leukemia of myeloid origin (Figure 2). Right sided lacrimal gland mass biopsy report revealed a myeloid sarcoma (Figure 3) confirmed by Myeloperoxidase [MPO] positivity (Figure 4).



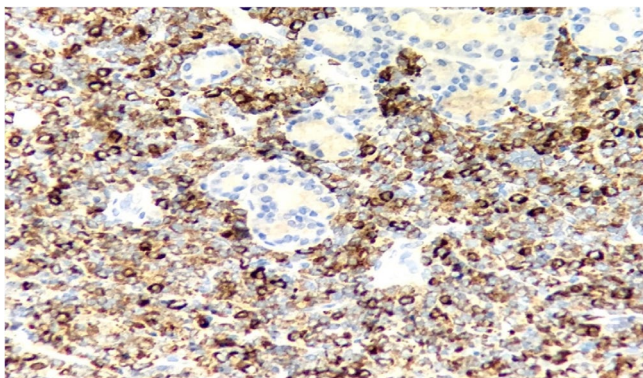
**Figure 1:** Peripheral smear: Showing myeloblasts (arrow) with Auer rods. [Leishman's stain: 1000x].



**Figure 2:** Bone marrow smear: Showing myeloblasts (arrow) with Auer rods. [Leishman's stain: 1000x].



**Figure 3:** Lacrimal gland biopsy: showing diffuse sheets of large blast cells resembling large cells infiltrating the lacrimal gland (acinar structures in 3A). [H&E: 40x].



**Figure 4:** Lacrimal gland biopsy: Showing infiltrates of myeloblasts with diffuse MPO positivity. [MPO: 40x].

## Discussion

GS [Granulocytic Sarcoma] (also called chloroma) was first described by the British physician, Burns A in 1811 [6]. The diagnosis of a GS can be difficult and sometimes it may be misdiagnosed. These tumors can occur anywhere in the body and they have to be differentiated from lymphomas, carcinomas or infectious process [7,8].

Due to the low incidence of myeloid (granulocytic) sarcoma, it is not possible to develop a proper algorithm for its diagnosis and treatment. Few descriptions that are available in the literature neither give an idea of the variety of manifestations and the order of organ involvement, nor allow any vital prognosis. Verification of the diagnosis can only be based on immunohistochemical findings of the primary tumor and bone marrow biopsy material [9].

In our case, the lacrimal gland architecture was effaced by infiltration of diffuse, monotonous population of immature myeloid or blast like cells, which on special stain turned out to be MPO positive. The bone marrow aspirates revealed proliferation of blast cells with Auer rods which were positive for myeloperoxidase stain. The peripheral blood smears also showed myeloblasts with Auer rods in the cytoplasm.

## Conclusion

The overall histopathologic appearance, peripheral blood smears and bone marrow smear findings with MPO positivity, was consistent with the diagnosis of extramedullary acute myeloid leukemia in the form of mass involving lacrimal gland [myeloid sarcoma].

Myeloid sarcoma, although rare, should be considered as one of the differentials when a paediatric patient presents with proptosis or eyelid swelling.

## References

1. Byrd JC, Weiss RB, Arthur DC, Lawrence D, Baer MR, et al. (1997) Extramedullary leukemia adversely affects hematologic complete remission rate and overall survival in patients with t(8;21)(q22; q22): results from Cancer and Leukemia Group B 8461. *J Clin Oncol* 15: 466-475.
2. Wani RM, Rashid S, Mir AM, Suraya S (2015) AML presenting as bilateral proptosis with lacrimal glands involvement in a young male. *Int J Med Res Rev* 3: 669-672.
3. Mitkowski D, Gil L (2017) Isolated myeloid sarcoma as the first manifestation of acute myeloid leukemia: A case study. *Clin Case Rep* 5: 1802-1806.
4. Rajput D, Naval R, Yadav K, Tungaria A, Behari S (2010) Bilateral proptosis and bi-temporal swelling: a rare manifestation of acute myeloid leukemia. *J Pediatr Neurosci* 5: 68-71.
5. Alkatan H, Chaudhry IA (2008) Myeloid sarcoma of the orbit. *Ann Saudi Med* 28: 461-465.
6. Kundu S, Chatterjee S, Mondol D, Dastidar AG, Roy A (2008) Extramedullary granulocytic sarcoma. *Indian J Med Paediatr Oncol* 29: 28-30.
7. Bangert M, Hildebrand A, Waidmann O, Griesshammer M (2000) Diagnosis of Granulocytic Sarcoma by Fine-Needle Aspiration Cytology. *Acta Haematol* 103: 102-108.
8. Brijesh Thakur, Kachnar Varma, Vatsala Misra, Smita Chauhan (2013) Granulocytic Sarcoma Presenting as an Orbital Mass: Report of Two Cases. *J Clin Diagn Res* 7: 1704-1706.
9. Likhvantseva VG, Safonova TN, Kuzmin KA (2016) Primary granulocytic sarcoma of lacrimal gland. *Vestn Oftalmol* 132: 82-89.



Addiction & Addictive Disorders  
Advances in Industrial Biotechnology  
Advances in Microbiology Research  
Agronomy and Agricultural Science  
AIDS Clinical Research & STDs  
Alcoholism, Drug Abuse & Substance Dependence  
Allergy Disorders and Therapy  
Alternative, Complementary & Integrative Medicine  
Alzheimer's & Neurodegenerative Diseases  
Anesthesia & Clinical care  
Angiology & Vascular Surgery  
Animal Research and Veterinary Science  
Aquaculture & Fisheries  
Archives of Urology  
Archives of Zoological Studies  
Atmospheric & Earth Sciences  
Biotech Research & Biochemistry  
Brain & Neuroscience Research  
Cancer Biology and Treatment  
Cardiology and Neurocardiovascular Diseases  
Cell Biology & Cell Metabolism  
Clinical Dermatology and Therapy  
Clinical Immunology & Immunotherapy  
Clinical Studies and Medical Case Reports  
Community Medicine & Public Health Care  
Current Trends: Medical & Biological Engineering  
Cytology & Tissue Biology  
Dentistry: Oral Health & Cosmesis  
Diabetes & Metabolic Syndrome Disorders  
Emergency Medicine, Trauma and Surgical Care  
Environmental Science: Current Research  
Food Science & Nutrition  
Forensic, Legal & Investigative Sciences  
Gastroenterology & Hepatology Research  
Genetics & Genomic Sciences  
Gerontology & Geriatric Medicine  
Hematology, Blood Transfusion & Disorders  
Hospice & Palliative Medical Care  
Human Endocrinology  
Infectious & Non Infectious Diseases  
Internal Medicine and Primary HealthCare  
Laser Research & Applications  
Medicine: Study & Research  
Modern Chemical Sciences  
Nanotechnology: Nanomedicine & Nanobiotechnology  
Neonatology and Clinical Pediatrics  
Nephrology & Renal Therapy  
Non-invasive Vascular Investigations  
Nuclear Medicine, Radiology & Radiation Therapy  
Obesity & Weight Loss  
Ophthalmology & Clinical Research  
Orthopedic Research & Physiotherapy  
Otolaryngology, Head and Neck Surgery  
Pathology: Clinical & Medical Research  
Pharmacology, Pharmaceutics & Pharmacovigilance  
Physical Medicine, Rehabilitation & Disabilities  
Plant Science: Current Research  
Practical and Professional Nursing  
Protein Research & Bioinformatics  
Psychiatry, Depression and Anxiety  
Pulmonary Medicine & Respiratory Research  
Reproductive Medicine, Gynaecology and Obstetrics  
Stem Cells Research, Development & Therapy  
Surgery: Current Trends & Innovations  
Toxicology: Current Research  
Translational Science and Research  
Vaccines Research and Vaccination  
Virology & Antivirals

Submit Your Manuscript: <http://www.heraldopenaccess.us/Online-Submission.php>