

Mini Review

Management of Hyperhidrosis: A Proposal Protocol for Trainees

Katherine V Hurst¹, Ashok Handa^{1*} and Andrew Gordon²

¹Nuffield Department of Surgical Sciences, University of Oxford, Oxford, UK

²Department of Vascular Surgery, John Radcliffe Hospital, Oxford, UK

Introduction

Hyperhidrosis is a chronic condition characterised by excessive sweating [1], and can affect up to 3% of the population [2]. It can be classed as generalised; involving all the body's sweat glands, or localized; affecting specific areas of the body only e.g., palms, soles of feet, groin [3].

The condition is seriously debilitating due to both emotional and social embarrassment. Some patients may also endure physical or occupational disability, hindering their activities of daily living and negatively impacting on their employability [4]. With this in mind it is important to treat patients with successful therapies and ensure adequate follow up is sought after the procedure.

Methods

An observational study aiming to highlight the treatments available for both palmar and plantar hyperhidrosis, following results within our single centre (Figure 1). No ethical approval was required for this study, and all patients gave informed consent at the time of procedure.

Results

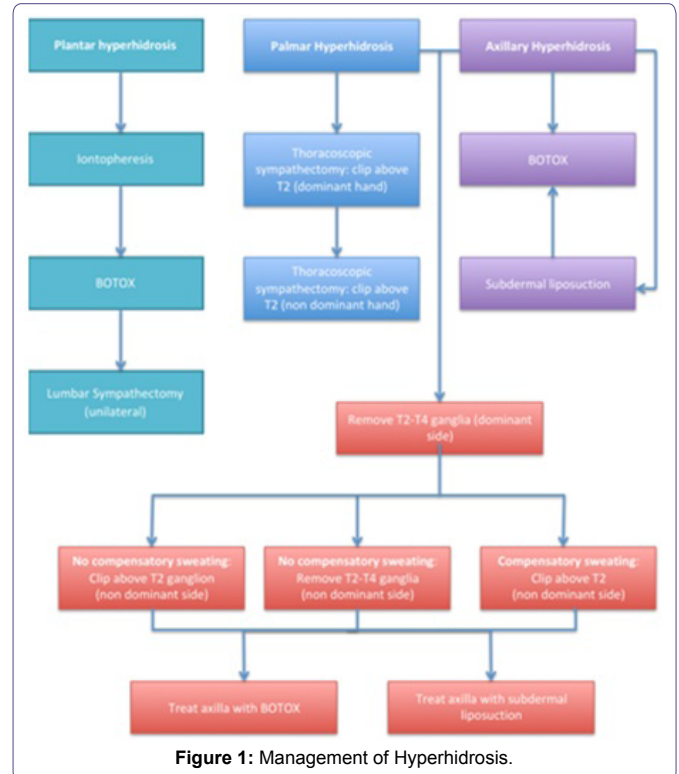
Plantar hyperhidrosis

Plantar hyperhidrosis has been successfully treated with iontophoresis for many years [5], but there is little understanding of its mechanism of action. It is believed to work by affecting the ion channels within the sweat glands, or by directly closing the pores within the skin. As a first line treatment, our centre finds an approximate cure rate of 70% when used for plantar hyperhidrosis, and these statistics are also supported in the literature [6].

*Corresponding author: Ashok Handa, Nuffield Department of Surgical Sciences, University of Oxford, Oxford, UK, Tel: +44 1865231067; E-mail: ashok.handa@nds.ox.ac.uk

Citation: Hurst KV, Handa A, Gordon A (2015) Management of Hyperhidrosis: A Proposal Protocol for Trainees. J Angiol Vasc Surg 1: 001.

Received: July 16, 2015; Accepted: December 03, 2015; Published: December 18, 2015



If this is unsuccessful, second line treatment should be the injection of Botulinum Toxin (BOTOX®) [7]. These injections achieve excellent results [4,8], but are extremely painful to administer and require repeated treatments. Our centre treats approximately 50 patients per year with BOTOX® therapy and only two of these cases have required treatment for plantar hyperhidrosis.

Although not advocated within our centre due to its complications, a possible third line treatment would be a lumbar sympathectomy. For male patients wishing to preserve erectile function, a unilateral sympathectomy would be advised [9]. Many centres would consider bilateral lumbar sympathectomy in female patients [10], but following reported cases of reduced libido after the procedure, we would not advocate bilateral treatment for either gender [9].

Palmar hyperhidrosis

In patients presenting with palmar hyperhidrosis only, treatment should be by thoracoscopic sympathectomy, on the dominant side only. This involves clipping just above the T2 ganglion. Advantages of clipping are that the cure rate for palmar hyperhidrosis is approximately 98% [11] and there is a 70% recovery if the clip needs to be removed because of severe compensatory sweating or other complication. If the nerve root is cut however, there is the potential for reoccurrence as the nerve grows back [12].

The pitfalls to this procedure are;

- 1) Failure; due to clipping the wrong ganglion, or to reoccurrence,
- 2) Compensatory sweating, particularly around the abdomen [13].

In the case of unilateral sympathectomy, compensatory sweating is rarely a problem, however if a patient requests a sympathectomy on the contralateral side, compensatory sweating of the back, abdomen and feet should be discussed prior to procedure.

Axillary hyperhidrosis

The treatment for axillary hyperhidrosis is controversial. There are two options; the first being the use of botulinum toxin injections as first line treatment [14]. These injections have good clinical outcomes but require repeated administration and can be painful for patients [15]. The mean time to subsequent injections is 18 months.

We have treated a total of 168 patients from 2007-2015, on a self referral basis. Some patients require injections every 4 months, whilst others only re-present after 2 years. General patient satisfaction is high and outcomes are reputable.

The second pathway involves referral to a plastic surgeon for subdermal liposuction as primary therapy. Although this treatment has a risk of seroma formation [16], it can be extremely effective in the long term and the seromas tend to settle with time. If this is unsuccessful, botulinum toxin injections could be considered.

Palmar and axillary hyperhidrosis

For patients who present with both palmar and axillary hyperhidrosis, the T2-T4 ganglia should be removed unilaterally, from their dominant side. This is extremely effective for palmar hyperhidrosis and significantly reduces sweating in 60-80% of patients [17]. It also prevents patients requiring repeated botulinum toxin injections to multiple areas [18].

Our unit has demonstrated reliable results following removal of the T2-T4 ganglia; however studies have shown similar long term outcomes following T3-T4 sympathectomy, and possible reduction in compensatory sweating [19].

If the patient wishes to have further treatment, there are several options available:

- 1) If no compensatory sweating has occurred, the T2-T4 (or T3-T4) ganglion can be removed from the contralateral side. An alternative option would be to clip above the T2 ganglion only on the contralateral side and treat the axilla with either botulinum toxin or subdermal liposuction, reducing the risk of compensatory sweating.
- 2) If compensatory sweating has occurred following treatment of the dominant side, the second option of clipping above the T2 ganglion and treating the axilla separately is advised.

If however the patient fails to have reduced axillary sweating after treatment, they can either be treated with botulinum toxin or subdermal liposuction bilaterally.

Our unit operates on approximately 6-8 patients per year for palmar and axillary hyperhidrosis. All have had adequate outcomes post procedure, with around 60% requesting further sympathectomy on their non dominant side.

Alternative Treatments

There are several alternative treatments, which can be considered in the management of hyperhidrosis. Topical aluminium chloride works by blocking and altering the configuration of the sweat ducts [20]. However many patients do not respond to the treatment or cannot tolerate the side effects of pain and/or itching [21].

Anticholinergic medications can be used either topically or orally. Multiple studies have evaluated their outcomes, and although their efficacy (topically and orally) is in the range of 60-75% [22], the side effects are marked and they are contraindicated in a wide range of patients [23].

Conclusion

Following successful results in our centre, we propose the above protocol (Figure 1) for the management of patients presenting with hyperhidrosis.

This research received no specific grant from any funding agency in the public, commercial, or not-for-profit sectors.

The authors declare no conflict of interest in preparing this article.

References

1. Lakraj AA, Moghimi N, Jabbari B (2013) Hyperhidrosis: anatomy, pathophysiology and treatment with emphasis on the role of botulinum toxins. *Toxins (Basel)* 5: 821-840.
2. Strutton DR, Kowalski JW, Glaser DA, Stang PE (2004) US prevalence of hyperhidrosis and impact on individuals with axillary hyperhidrosis: results from a national survey. *J Am Acad Dermatol* 51: 241-248.
3. Stashak AB, Brewer JD (2014) Management of hyperhidrosis. *Clin Cosmet Investig Dermatol* 7: 285-299.
4. Naumann MK, Hamm H, Lowe NJ, Botox Hyperhidrosis Clinical Study Group (2002) Effect of botulinum toxin type A on quality of life measures in patients with excessive axillary sweating: a randomized controlled trial. *Br J Dermatol* 147: 1218-1226.
5. Daghfous M, Zghal M, Zghal A, Cherif F, Kamoun MR (1993) [Treatment of palmar and plantar hyperhidrosis by ++ionophoresis]. *Tunis Med* 71: 387-389.
6. McAleer MA, Collins P (2014) A study investigating patients' experience of hospital and home iontophoresis for hyperhidrosis. *J Dermatolog Treat* 25: 342-344.
7. Dressler D, Adib Saberi F (2013) Towards a dose optimisation of botulinum toxin therapy for axillary hyperhidrosis: comparison of different Botox® doses. *J Neural Transm* 120: 1565-1567.
8. Naumann M, Lowe NJ (2001) Botulinum toxin type A in treatment of bilateral primary axillary hyperhidrosis: randomised, parallel group, double blind, placebo controlled trial. *BMJ* 323: 596-599.
9. Takats G, Helfrich L (1941) Sterility of the males after sympathectomies. *JAMA* 117: 20-21.
10. Loureiro Mde P, de Campos JR, Kauffman P, Jatene FB, Weigmann S, et al. (2008) Endoscopic lumbar sympathectomy for women: effect on compensatory sweat. *Clinics (Sao Paulo)* 63: 189-196.
11. Solish N, Bertucci V, Dansereau A, Hong HC, Lynde C, et al. (2007) A comprehensive approach to the recognition, diagnosis, and severity-based treatment of focal hyperhidrosis: recommendations of the Canadian Hyperhidrosis Advisory Committee. *Dermatol Surg* 33: 908-923.
12. Fox AD, Hands L, Collin J (1999) The results of thoracoscopic sympathetic trunk transection for palmar hyperhidrosis and sympathetic ganglionectomy for axillary hyperhidrosis. *Eur J Vasc Endovasc Surg* 17: 343-346.
13. Licht PB, Pilegaard HK (2004) Severity of compensatory sweating after thoracoscopic sympathectomy. *Ann Thorac Surg* 78: 427-431.
14. Scamoni S, Valdatta L, Frigo C, Maggiulli F, Cherubino M (2012) Treatment of Primary Axillary Hyperhidrosis with Botulinum Toxin Type A: Our Experience in 50 Patients from 2007 to 2010. *J ISRN Dermatol*.

15. Naumann M, Lowe NJ, Kumar CR, Hamm H, Hyperhidrosis Clinical Investigators Group (2003) Botulinum toxin type A is a safe and effective treatment for axillary hyperhidrosis over 16 months: a prospective study. Arch Dermatol 139: 731-736.
16. Dixit VV, Wagh MS (2013) Unfavourable outcomes of liposuction and their management. Indian J Plast Surg 46: 377-392.
17. Smidfelt K, Drott C (2011) Late results of endoscopic thoracic sympathectomy for hyperhidrosis and facial blushing. Br J Surg 98: 1719-1724.
18. Glaser DA, Hebert AA, Pariser DM, Solish N (2007) Palmar and plantar hyperhidrosis: best practice recommendations and special considerations. Cutis 79: 18-28.
19. Scognamillo F, Serventi F, Attene F, Torre C, Paliogiannis P, et al. (2011) T2-T4 sympathectomy versus T3-T4 sympathicotomy for palmar and axillary hyperhidrosis. Clin Auton Res 21: 97-102.
20. Stolman LP (2003) Treatment of hyperhidrosis. J Drugs Dermatol 2: 521-527.
21. Rayner CR, Ritchie ID, Stark GP (1980) Axillary hyperhidrosis, 20% aluminum chloride hexahydrate, and surgery. Br Med J 280: 1168.
22. Wolosker N, de Campos JR, Kauffman P, Yazbek G, Neves S, et al. (2013) Use of oxybutynin for treating plantar hyperhidrosis. Int J Dermatol 52: 620-623.
23. Wolosker N, de Campos JR, Kauffman P, Puech-Leão P (2012) A randomized placebo-controlled trial of oxybutynin for the initial treatment of palmar and axillary hyperhidrosis. J Vasc Surg 55: 1696-1700.