

Case Report

COVID-19 Related Acute Lower Limb Ischemia Treated Via Percutaneous Thrombectomy and Catheter Direct Thrombolysis

Francesco De Santis*, Roberto Chiappa, Maria Paola Notari, Cristina Chaves and Massimiliano Millarelli

Department of Vascular Surgery, Sandro Pertini Hospital, Rome, Italy

Abstract

Background: The aim of this report is to describe and discuss a unique case of acute lower limb ischemia presented in a recovered COVID-19 patient treated via percutaneous mechanical thrombectomy and catheter directed thrombolysis. Starting from this singular case a wide literature review regarding COVID-19-related thrombo-embolic complications has been accomplished.

Methods: A 47-year-old male was admitted to the emergency unit with acute lower limb ischemia three weeks after testing positive for COVID-19. He had been isolated at home because of minor COVID-19-related symptoms. Angio-CT-imaging showed a segmental occlusion of the common iliac artery coupled with retro-articular popliteal artery and leg vessels thrombosis. The patient was first unsuccessfully submitted to trans-femoral iliac thrombo-embolctomy.

Results: Instead of peripheral limb vessel re-thromboembolctomy, a percutaneous mechanical thrombectomy coupled with leg vessel catheter direct thrombolysis was performed. The completion angiography showed the recanalization of the popliteal artery and leg vessels as far as the ankle but with a reduced forefoot vascularization.

The fibrinolytic treatment was continued for 8 hours post-operatively. A compartment syndrome complicated the early post-operative course. There was a progressive recovery of ischemic symptoms and at 6-month follow-up, peripheral pulses were palpable with an almost complete normalization of foot and toe perfusion and motility.

*Corresponding author: Francesco De Santis, Department of Vascular Surgery, Sandro Pertini Hospital, Rome, Italy, Tel +39 3205796447; E-mail: f.desantis6@virgilio.it

Citation: De Santis F, Chiappa R, Notari MP, Chaves C, Millarelli M (2021) COVID-19 Related Acute Lower Limb Ischemia Treated Via Percutaneous Thrombectomy and Catheter Direct Thrombolysis. J Angiol Vasc Surg 6: 080.

Received: December 12, 2021; **Accepted:** December 15, 2021; **Published:** December 22, 2021

Copyright: © 2021 De Santis F, et al. This is an open-access article distributed under the terms of the Creative Commons Attribution License, which permits unrestricted use, distribution, and reproduction in any medium, provided the original author and source are credited.

Conclusion: Acute lower limb ischemia following COVID-19-related arterial thrombo-embolic events represents a severe complication of COVID-19 infection and may result in a high rate of revascularization failure. In these cases, Percutaneous Mechanical thrombectomy coupled with catheter directed thrombolysis might represent a less traumatic and more selective approach.

Keywords: Catheter direct thrombolysis; COVID-19 related acute lower limb ischemia; Endovascular treatment; Percutaneous mechanical thrombectomy; Thrombo-embolic complications

Introduction

COVID-19 infection should be considered a very complex systemic disease, not limited to the lungs [1,2]. Between 20 and 55% of COVID-19 infected patients can develop abnormal coagulation characterized by significant increase in D-dimer level, Thromboplastin Time Alteration (*aPTT*) and high fibrinogen level [1,2]; furthermore, over 80% of COVID-19 patients present a maximal clot amplitude at thrombo-elastography analysis above normal value [3].

Biomarkers related to coagulation coupled with platelet activation and inflammation have also been suggested as useful prognostic tools for COVID-19-associated coagulopathy [4].

As a consequence of this hypercoagulability, the haemostatic system in these cases is evidently shifted toward the procoagulant state [1-4].

Actually, this specific condition predisposes these patients to venous and, more rarely, arterial thromboembolic events [5-10]. These may occur not only in elderly men with cardiovascular comorbidities, obesity or in critically ill patients with Acute Respiratory Distress Syndrome (ARDS) but also in relatively young males with minor COVID-19 infection-related symptoms and without evident comorbidities or significant pre-existing atherosclerotic lesions [7,8,11-15].

The exact mechanism of COVID-19-related arterial thromboembolic events is still not fully understood and similarly, limited studies are available regarding the etiopathogenesis of the systemic macro and microangiopathy that can frequently affect these patients [2,10].

Also, the proper management of COVID-19-related arterial thrombosis is still not well defined; however, it has been reported that this can frequently be very challenging and the outcome often results in failure of limb revascularization [8,9,16].

The aim of this report is to describe and discuss a singular case of acute lower limb ischemia developed in a young, recovered male patient, not affected by significant comorbidities or pre-existing atherosclerotic lesions. He had been successfully treated via percutaneous mechanical thrombectomy and catheter directed thrombolysis following unsatisfactory trans-femoral surgical thrombo-embolctomy. Starting from this singular case a wide literature review regarding this challenging COVID-19-related complication has been accomplished.

Case Report

Three weeks after diagnosis of COVID-19 infection, a 47-year-old male patient arrived at the emergency unit of another hospital with severe right lower limb pain coupled with numbness and reduced motor function of the whole foot which had started three days earlier. He had no relevant medical history, atherosclerosis, atrial fibrillation, or pre-existing blood clotting disorders, and had been isolated at home because of minor COVID-19 symptoms (fever 38°, cough and general malaise coupled with a positive coronavirus swab). An initial observation showed that he had completely recovered.

The physical examination revealed that the right foot was cyanosed and cold, with significant reduction in mobility. No femoral artery or other peripheral pulses of the right lower extremity were palpable while all the contralateral peripheral pulses were perceptible.

The initial laboratory evaluation, evidenced leucocytosis (WBC count $18,40 \times 10^3$), with an absolute neutrophil count of 88,6; haemoglobin, platelets and renal functionality were in normal range. However, coagulation was abnormal because of thromboplastin time alteration (aPTT: 18,0 sec.), and increased D-dimer (802 ng/ml ;). In addition, a significant muscular enzyme increase creatinine kinase (551 U/L) was evidenced. Hemogas analysis was not significant for hypoxemia and respiratory alkalosis.

Preoperative computed tomography angiography with volume rendering 3-dimensional reconstruction showed a segmental thrombosis of the right common iliac artery coupled with hypogastric occlusion (Figure 1 A-D) and retroarticular popliteal artery thrombosis with almost total absence of leg and foot perfusion (Figure 2 A-D).

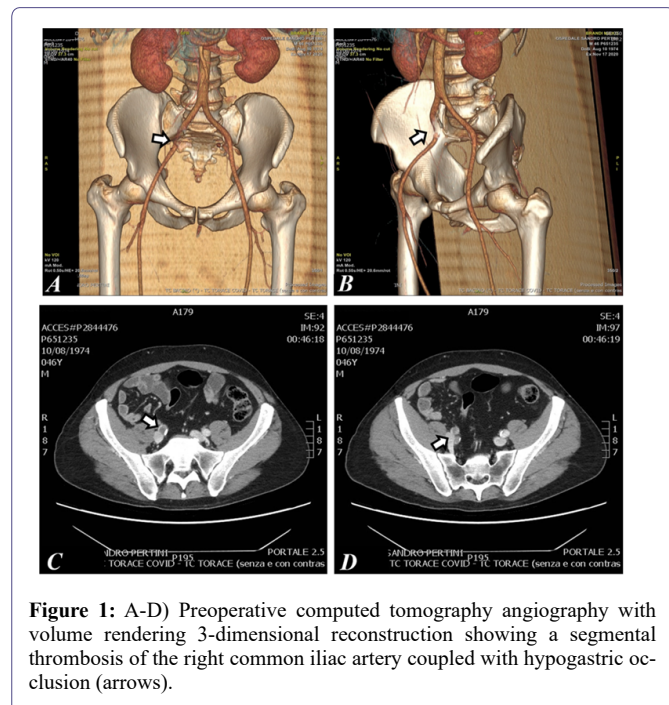


Figure 1: A-D) Preoperative computed tomography angiography with volume rendering 3-dimensional reconstruction showing a segmental thrombosis of the right common iliac artery coupled with hypogastric occlusion (arrows).

The transthoracic echocardiogram was negative for intra-cardiac thrombus and ejection fraction was 55-60%. The patient was administered therapeutic anticoagulation therapy with unfractionated Heparin and underwent open trans-femoral thromboembolectomy (no competition angiography was performed). The arteries were inspected during surgery, and found free of macroscopic atherosclerotic disease.

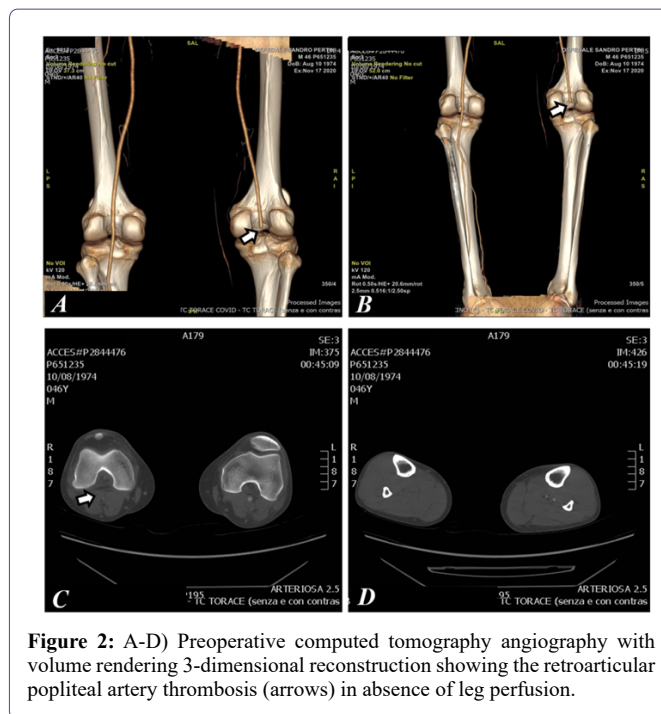


Figure 2: A-D) Preoperative computed tomography angiography with volume rendering 3-dimensional reconstruction showing the retroarticular popliteal artery thrombosis (arrows) in absence of leg perfusion.

Post thromboembolectomy, the patient did not present a significant clinical picture recovery; only the femoral artery pulse was palpable, and was therefore transferred to our vascular surgery hub.

On admission, the patient still presented an ischemic right limb with persistent significant reduction of feeling and motor function in the foot including the toes.

The Eco-color-Doppler evaluation showed a direct flow at the common and superficial femoral artery level but confirmed the occlusion of the retroarticular popliteal artery with very low residual flow in the leg vessels.

After careful imaging and clinical picture evaluation, in order to achieve a more selective mini-invasive approach and reduce the overall surgical trauma, we decided to perform an endovascular lower limb revascularization based on percutaneous mechanical thrombectomy using Indigo System® (Penumbra, Almeida, California), instead of surgical re-thromboembolectomy of the leg vessels.

In order to avoid arterial puncture at the previous common femoral artery surgical site, a percutaneous US-guided antegrade superficial femoral arterial approach was made, and a straight, 6-F, 11 cm sheath (Destination®, Terumo Europe) was advanced into the proximal popliteal artery. After full systemic heparinization, the Indigo System® was set up, and the largest, non-occlusive catheter possible, CAT5, was advanced over a 0.035-inch wire into the thrombo-embolus. After reaching full vacuum in the Pump MAX®, the flow switch was turned on, the organized thrombus was aspirated, then the catheter was withdrawn proximally. The angiographic control showed complete recanalization of the popliteal artery and a partial reperfusion of the tibialis anterior and tibio-peronealis trunk (Figure 3A-B). Further clots were subsequently aspirated from the three leg vessels and an intra-arterial loco-regional direct thrombolysis (Urokinase 100,000 IU in 50 ml saline solution in elastomer) was then performed. The completion angiography showed recanalization of the popliteal artery as well as of the tibialis anterior and posterior arteries, partial

recanalization of the interosseous artery as far as the ankle (Figures 3C-3F) but a significantly slowed flow in the limb vessels and a reduced forefoot and toes vascularization (Figure 3F - miniature). After the operation, both peripheral pulses were palpable.

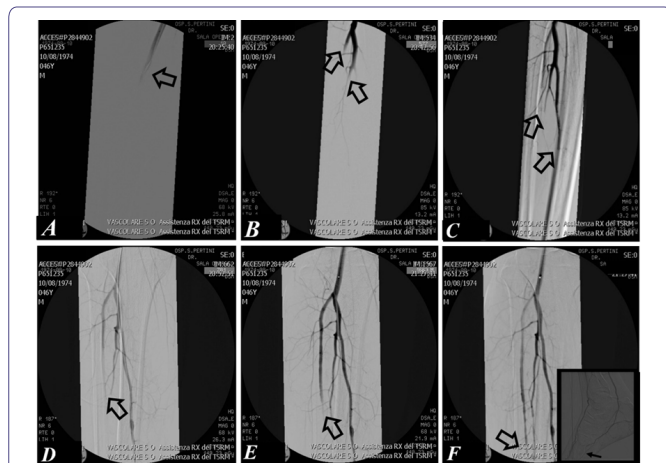


Figure 3: (A-F) First angiographic control before percutaneous mechanical thrombectomy via Indigo System (Penumbra, Almeida, California) showing the retroarticular popliteal artery occlusion with no peripheral leg vessels vascularization (arrow) (A); angiographic control performed after mechanical thrombectomy showing the complete recanalization of the popliteal artery with partial reperfusion of the tibialis anterior and tibioperonealis trunk (arrow) (B); angiographic controls performed after further clot aspiration from the three leg vessels and intra-arterial loco-regional direct thrombolysis (Urokinase 100,000 IU in 50 ml saline solution), showing the progressive recanalization of the tibialis anterior and posterior and the partial recanalization of the interosseous artery as far as the ankle with a significantly slowed flow (arrows) (C-F); the miniature shows the reduced forefoot perfusion (small black arrow) (Figure 3 F).

The fibrinolytic treatment was continued for 8 hours post-operatively (75,000 IU every hour) and then stopped because of bleeding in the thigh and groin region. This was resolved via prolonged local compression (after removing the introducer and US-guided arterial access closure via Perclose ProGlide SMC System).

The postoperative medical therapy consisted of intravenous Heparin infusion (continuous intravenous Heparin to reach an activated partial thromboplastin time of 2.0 seconds in elastomer), coupled with continuous intra-arterial Prostaglandin intravenous infusion (Iloprost 1 fl in 50 ml saline solution in elastomer).

After limb revascularization, a significant progressive increase in muscular enzyme creatinine kinase was observed (up to a maximum of 9179 U/L), coupled with the development of a compartment syndrome that required emergency medical and lateral leg fasciotomy ca. 24 hours after limb revascularization; however, no evidence of thrombocytopenia or renal function deterioration was evidenced.

In the subsequent postoperative course, the patient experienced a progressive normalization of blood parameters and recovery of the clinical picture. He was discharged three weeks postoperatively under double antiplatelet therapy (*ASA* + Clopidogrel) and remained isolated at home. The Coronavirus swab persisted to be positive for two weeks after discharge. At six-month follow-up, both peripheral pulses were still palpable and the Eco-color-Doppler control documented direct flow in the popliteal, tibialis anterior and posterior artery. An almost complete normalization of foot and toe motility and sensibility were observed, with a mild residual hypoesthesia in the forefoot due to persistent peroneal and tibialis nerve post-ischemic neuropathy (confirmed via electromyography).

Discussion

Patients with COVID-19 infection often present a significant pro-coagulant state frequently related to the severity of the clinical picture [1,2,5].

This condition, together with the inflammatory state associated with endotheliitis induced by direct viral infection (characterized histologically by diffuse endothelial damage and infiltration by inflammatory cells), can act as a trigger for thrombo-embolic events [9,10,14].

The spectrum of appearance of this complication is extremely wide, including deep-vein thrombosis and associated pulmonary embolism, as well as, more rarely, arterial thrombosis [2,9,17-21].

These can involve both the coronary circulation [22,23], as well as brain [22,24], mesenteric aortoiliac and peripheral arterial systems [8,22,25].

The overall incidence of COVID-19-related venous or arterial thrombo-embolic events is yet to be defined with certainty. In a recent systematic review analysis including 2928 patients in 28 studies, thrombo-embolic complications occurred in 34% of the intensive care unit managed patients. In detail, 16.1% of these presented deep venous thrombosis and 12,6% experienced pulmonary embolism; in this study arterial thromboembolic events are more rarely reported; specifically, cerebrovascular accidents and a myocardial infarction were observed in only 3.0% and 8,0% of cases respectively; only 39 out of 1566 considered patients (2.5%) experienced a limb or mesenteric ischaemia [2].

In another single-center retrospective analysis on the prevalence of thrombotic complications detected with systematic CT Scanning, including 72 critically ill patients with COVID-19 infection admitted to the intensive care unit for acute respiratory distress syndrome, 54 thrombotic complications were detected in 42 patients (58%). These affected the pulmonary artery in 34 cases (47%) and the peripheral venous system in 15 (21%); in this study, (7%) a systemic arterial thromboembolic complication was evidenced in only five cases [20]. It is interesting to note how, unexpectedly, biomarkers of coagulation or inflammation did not discriminate between patients with or without thrombotic complications detected via systemic CT imaging on admission [20].

Klok, et al. in a study including 184 patients on the incidence of thrombotic complications in critically ill intensive care unit COVID-19 patients reported an overall incidence of thrombo-embolic events of 31%. Also in this study, only 3.7% of these were represented by arterial thrombosis, three of these causing an ischemic stroke [26].

On the contrary, Topcu, et al. reported only six cases (0,9%) of acute limb ischemia on a total of 681 consecutive COVID-19 patients [10], ninety (13.2%) of which requiring intensive care unit admission. Three of these received only systemic anticoagulation while three underwent surgical thrombectomy [10].

Finally, Cheruiyot, et al. conducted a systematic review of current scientific literature published between November 1st 2019, and June 9, 2020, on PubMed and China National Knowledge Infrastructure to investigate the incidence, clinical and anatomical characteristics of arterial thrombotic events occurring in COVID-19 patients. This

review included 27 studies (5 cohort, 5 case series, and 17 case reports) and overall, 90 COVID-19-infected patients. Analysing the results of this wide review-study the Authors concluded that arterial thrombosis can occur in around 4% of critically ill COVID-19 patients; ca. 18% of thrombotic events affected multiple arteries and more than 95% of these presented severe ischemic symptoms [9].

In contrast, in a more recent study by de Roquetaillade, et al. an unusually high rate of arterial thrombo-embolic events in COVID-19 infected patients was reported. In fact, in this study, including 209 cases of European COVID-19 patients, the rate of arterial thrombo-embolisms, resulted in 9.6% (24 events in 20 patients considered) compared to a mean incidence of 3.7 - 4.4% reported in the largest previously published series [3,7- 10, 14-16,26].

It is interesting to note that in this study, according to what emerges from similar, more recent reports [9,10], arterial thrombotic events in COVID-19 infections can also involve relatively young patients without pre-existing atherosclerotic lesions [15]. It is also worth pointing out that surprisingly, no significant blood test abnormalities in coagulation parameters were found [15].

Our patient was a 47-year-old man with no relevant past medical history, atherosclerosis, atrial fibrillation, or pre-existing blood clotting disorders but only minor coagulation abnormalities on admission as reported above.

The onset of COVID-19-related arterial thrombosis can be extremely variable.

In some cases, arterial thrombosis can develop later in patients initially hospitalized for COVID-19-related pneumonia. Mellissano, et al. showed a significant number of these late-development COVID-19 complications three weeks after hospitalization, presenting with peripheral ischemia of both lower limbs and, occasionally, upper limbs, all requiring treatment [12].

In other rarer cases, on the contrary, acute lower limb ischemia represents the initial symptom of COVID-19 disease and can precede the onset of respiratory symptoms [7].

Finally, this complication can also arise after patients have recovered from major symptoms [2,8-10,12] of COVID-19.

In our case, acute leg ischemia developed three weeks after mild COVID-19 infection when he had already recovered from minor symptoms and was completely asymptomatic, in isolation because of a positive swab. The coagulation anomalies were characterized only by mild thromboplastin time alteration (aPTT: 18,0 sec.; nv: 22,0-31,00), and increased D-dimer level (802 ng/ml; nv: 2-349).

Acute limb ischemia due to COVID-19-related thromboembolic events can affect both lower and upper extremities as well as, rarely, vascular grafts [5,11,27].

As reported in other surgical series, arterial thrombosis may frequently interest multiple vascular levels [2,7,8,10]. Also in our case, Angio-CT imaging showed the segmental occlusion of the common iliac artery (Figure 1 A-D) (initially treated with surgical thrombectomy), coupled with the retro-articular popliteal artery thrombosis in absence of leg vessels perfusion (Figure 2 A-D).

The most frequent therapeutic options experienced in presence of COVID-19-related arterial thromboembolic events include, surgical thrombo-embolism, eventually coupled with intraoperative local thrombolysis or, less frequently, surgical by-pass [2,6,8,10,12,22].

However, the prognosis of COVID-19-related thromboembolic events is frequently poor and the failure of limb revascularization is usually very high [2,8,10,16].

Mellisano, et al in a study on a pattern of vascular disease in Lombardy including 21 cases of lower limb ischemia during the first month of the COVID-19 outbreak showed a tendency to have advanced ischemia and below the knee thrombosis. In this study ca. one third of the included patients (28,5%) underwent major amputation (6 out of 21 cases) [12].

Similarly, Bellosta, et al. in a large study series on acute limb ischemia developed in patients with COVID-19 infection, including 20 patients affected by COVID-19-related pneumonia, reported a higher failure rate of revascularization surgery [8]. Specifically, 17 out of 20 patients (85%) underwent surgery, while three of these (15%) did not undergo revascularization due to their moribund condition. In this series 20 surgical thrombo-embolisms were performed, of which four patients (23.5%) were also associated with intra-operative thrombolysis. Overall, successful revascularization was obtained in 12 out of the 17 (70.6%) operated. During hospitalization, 2 patients (13%) underwent re-intervention. This cohort of patients also revealed a high mortality rate (40%) [8].

Goldman, et al. in a retrospective propensity score-matched study on lower-extremity arterial thrombosis associated with COVID-19, compared 16 patients who tested positive for severe COVID-19-related acute respiratory syndrome from March to April 2020 and 32 patients who tested negative observed over three different periods of time (January -April 2018, January - April 2019, and January - April 2020) [18]. In this study, a high rate of leg amputation (25%) and death (38%) was also found in patients with COVID-19 compared with the control group (3% for both). A greater clot extension and a worst prognosis were also demonstrated in this series, especially in presence of severe systemic or respiratory symptoms [16].

As reported in several surgical series, arterial thrombotic events causing acute limb ischemia in COVID-19 patients often interested also the microcirculation vessels [2,3,7,8,14,28]. In these cases, there is a reduction or, even a total absence of the forefoot microcirculation at completion angiography after thrombectomy, as we found in a "desert foot" [7,8].

It is most likely that frequent reduction or absence of forefoot perfusion significantly conditions revascularization results. It has also been hypothesized that the frequent condition of "desert foot" might be related to the systemic, virus-related state of hypercoagulability [8].

Also, in our case the completion angiography showed a significantly slowed flow in the leg vessels coupled with a reduced forefoot vascularization (Figure 3 F – miniature).

In order to achieve a selective non-traumatic limb recanalization, we decided to perform a PMT rather than peripheral limb vessels re-thromboembolism. We have not found other cases of acute lower limb ischemia due to COVID-19-related arterial thrombo-embolic events managed successfully via percutaneous mechanical thrombo-aspiration in previously reported surgical series.

We employed a percutaneous US-guided superficial femoral artery approach to avoid puncturing at the same level as the previous arteriotomy at the common femoral artery level and, considering

the presence of distal leg and foot vessels thrombosis, a selective loco-regional direct catheter-guided intra-arterial thrombolysis. The fibrinolytic treatment was continued for 8 hours post-operatively and stopped due to bleeding in the thigh and groin region.

This treatment has also been reported in other experiences as an adjunctive intraoperative procedure in similar cases of COVID-19-related peripheral limb and foot vessel thrombosis [2,6,8,12,22].

The postoperative medical therapy consisted of continuous intravenous Heparin infusion, coupled with antiplatelet therapy and continuous intravenous Prostaglandin infusion.

In this regard, it has been suggested by some Authors that prolonged systemic heparin might improve not only patients' survival but also the possibility of limb salvage [2,8,9], preventing both propagation of the thrombus both proximally and distally and maintaining collateral vessels patency [4].

Furthermore, it seems that Heparin has a suppressive activity against the development of a cytokines storm, which is a typical pathogenetic process of COVID-19 infection that ultimately results in acute lung injury and death [29]. Finally, it has also been postulated that Heparin has a competitive binding activity to the coronavirus resulting in inhibiting cell organism penetration [4].

We did not document Heparin-induced thrombocytopenia in this case although this risk should always be considered (HIT) [19].

Conclusion

Acute lower limb ischemia following COVID-19-related arterial thrombo-embolic events represents a severe complication of COVID-19 infection and in these cases the failure of limb revascularization is usually very high.

An endovascular treatment via PMT coupled with CDT might represent a promising, less traumatic and more selective approach.

Conflict of Interest: The authors declare that there is no conflict of interest.

Acknowledgment

The authors wish to thank Ms Elena Harwood for the linguistic revision of this paper and BI Niccolò Vallone for the technical support.

References

1. Varga Z, Flammer AJ, Steiger P, Haberecker M, Andermatt R, et al. (2020) Endothelial cell infection and endotheliitis in COVID-19. *Lancet* 395: 1417-1418.
2. Jenner WJ, Kanji R, Mirsadraee S, Gue YX, Price S, et al. (2021) Thrombotic complications in 2928 patients with COVID-19 treated in intensive care: a systematic review. *J Thromb Thrombolysis* 51: 595-607.
3. Panigada M, Bottino N, Tagliabue P, Grasselli G, Novembrino C, et al. (2020) Hypercoagulability of COVID-19 patients in Intensive Care Unit. A report of thromboelastography findings and other parameters of hemostasis. *J Thromb Haemost* 7: 1738-1742.
4. Manolis AS, Manolis TA, Antonis A, Papatheou D, Melita H (2021) COVID-19 Infection: Viral Macro- and Micro-Vascular Coagulopathy and Thromboembolism/Prophylactic and Therapeutic Management *J Cardiovasc Pharmacol and Therap* 26: 12-24.
5. Kaur P, Qaqa F, Ramahi A, Shamon Y, Singhal M, et al. (2020) Acute upper limb ischemia in a patient with COVID-19. *Hematol Oncol Stem Cell Ther* 14: 348-350.
6. Baccellieri D, Apruzzi L, Ardita V, Rinaldi E, Bertoglio L, et al. (2020) The "venous perspective" in Lombardia (Italy) during the first weeks of the COVID-19 epidemic. *Phlebology* 5: 295-296.
7. Mietto C, Salice V, Matteo Ferraris M, Zuccon G, Valdambri F, et al. (2020) Acute Lower Limb Ischemia as Clinical Presentation of COVID-19 Infection *Ann Vasc Surg* 69: 80-84.
8. Bellosta R, Luzzani L, Natalini G, Pegorer MA, Attisani L, et al. (2020) Acute limb ischemia in patients with COVID-19 pneumonia. *J Vasc Surg* 6: 1864-1872.
9. Cheruyot I, Kipkorir V, Ngure B, Misiani M, Munguti J, et al. (2021) Arterial Thrombosis in Coronavirus Disease 2019 Patients: A Rapid Systematic Review. *Ann Vasc Surg* 1: 273-281.
10. Topcu CA, Ozturk-Altunyurt G, Akman D, Batirel A, Demirhan R (2021) Acute Limb Ischemia in Hospitalized COVID-19 Patients. *Ann Vasc Surg* 74: 88-94
11. Menter T, Haslbauer JD, Nienhold R, Savic S, Hopfer H, et al. (2020) Post-mortem examination of COVID-19 patients reveals diffuse alveolar damage with severe capillary congestion and variegated findings in lungs and other organs suggesting vascular dysfunction. *Histopathology* 2: 198-209.
12. Melissano G, Mascia D, Baccellieri D, Kahlberg A, Bertoglio L, et al. (2020) Pattern of vascular disease in Lombardy, Italy, during the first month of the COVID-19 outbreak. *J Vasc Surg* 1: 4-5.
13. Zhou B, She J, Wang Y, Ma X (2020) Venous thrombosis and Arteriosclerosis Obliterans of lower Extremities in a Very severe patient with 2019 novel coronavirus disease: a case report. *J Thromb Thrombolysis* 50: 229-232.
14. Indes JE, Koleilat I, Hatch NA, Choinski K, Jones DB, et al. (2021) Early experience with arterial thromboembolic complications in patients with COVID-19. *J Vasc Surg* 73: 381-389.
15. de Roquetaillade C, Chousterman BG, Tomasoni D, Zeitouni M, Houdart E, et al. (2021) Unusual arterial thrombotic events in Covid-19 patients. *Int. J Cardiol* 15: 281-284.
16. Goldman IA, Ye K, Scheinfeld MH (2020) Lower-extremity Arterial Thrombosis Associated with COVID-19 Is Characterized by Greater Thrombus Burden and Increased Rate of Amputation and Death. *Radiology* 2: 263-269.
17. Xiong M, Liang X, Wei YD (2020) Changes in blood coagulation in patients with severe coronavirus disease 2019 (COVID_19): A meta_analysis. *Br J Haematol* 189: 1050-1063.
18. Tang N, Li D, Wang X, Sun Z (2020) Abnormal coagulation parameters are associated with poor prognosis in patients with novel coronavirus pneumonia. *J Thromb Haemost* 18: 844-847
19. Warkentin TE, Kaatz S (2020) COVID-19 versus HIT hypercoagulability. *Thromb Res* 196: 38-51
20. Mirsadraee S, Gorog DA, Mahon CF, Rawal B, Semple TR, et al. (2021) Prevalence of Thrombotic Complications in ICU-Treated Patients With Coronavirus Disease 2019 Detected With Systematic CT Scanning *Crit Care Med* 49: 804-815.
21. Wichmann D, Sperhake JP, Lütgehetmann M, Steurer S, Edler C, et al. (2020) Autopsy findings and venous thromboembolism in patients with COVID-19. *Ann Intern Med* 4: 268- 277.
22. Lodigiani C, Iapichino G, Carenzo L, Cecconi M, Ferrazzi P, et al. (2020) Venous and arterial thromboembolic complications in COVID-19 patients admitted to an academic hospital in Milan, Italy. *Thromb Res* 191: 9-14
23. Dominguez-Erquicia P, Dobarro D, Raposeiras-Roubin S, Bastos-Fernandez G, Iñiguez-Romo A (2020) Multivessel coronary thrombosis in a patient with COVID-19 pneumonia. *Eur Heart J* 22: 2132.
24. Hess DC, Eldahshan W, Rutkowski E (2020) COVID-19-related stroke. *Transl Stroke Res* 11: 322-325.

25. Vulliamy P, Jacob S, Davenport RA (2020) Acute aorto-iliac and mesenteric arterial thromboses as presenting features of COVID-19. *Br J Haematol* 189: 1050-1063.
26. Klok FA, Kruip MJHA, van der Meer NJM, Arbous MS, Gommers D, et al. (2020) Confirmation of the high cumulative incidence of thrombotic complications in critically ill ICU patients with COVID-19. *Thrombosis Research* 191: 145-147.
27. Giacomelli E, Dorigo W, Fargion A, Calugi G, Cianchi G, et al. (2020) Acute thrombosis of an aortic prosthetic graft in a patient with Severe COVID-19e related pneumonia. *Ann Vasc Surg* 66: 8-10.
28. Cañas EG, Gaibar AG, Lorenzo LR, Rios JGC, Toiran AM, et al. (2020) Acute peripheral arterial thrombosis in COVID-19. Role of endothelial inflammation *Br J Surg* 10: 444-445.
29. Mehta Y, Dixi SB, Zirpe KG (2020) Cytokine Storm in Novel Coronavirus Disease (COVID-19): Expert Management Considerations *Indian J Crit Care Med* 6: 429-434.



- Advances In Industrial Biotechnology | ISSN: 2639-5665
- Advances In Microbiology Research | ISSN: 2689-694X
- Archives Of Surgery And Surgical Education | ISSN: 2689-3126
- Archives Of Urology
- Archives Of Zoological Studies | ISSN: 2640-7779
- Current Trends Medical And Biological Engineering
- International Journal Of Case Reports And Therapeutic Studies | ISSN: 2689-310X
- Journal Of Addiction & Addictive Disorders | ISSN: 2578-7276
- Journal Of Agronomy & Agricultural Science | ISSN: 2689-8292
- Journal Of AIDS Clinical Research & STDs | ISSN: 2572-7370
- Journal Of Alcoholism Drug Abuse & Substance Dependence | ISSN: 2572-9594
- Journal Of Allergy Disorders & Therapy | ISSN: 2470-749X
- Journal Of Alternative Complementary & Integrative Medicine | ISSN: 2470-7562
- Journal Of Alzheimers & Neurodegenerative Diseases | ISSN: 2572-9608
- Journal Of Anesthesia & Clinical Care | ISSN: 2378-8879
- Journal Of Angiology & Vascular Surgery | ISSN: 2572-7397
- Journal Of Animal Research & Veterinary Science | ISSN: 2639-3751
- Journal Of Aquaculture & Fisheries | ISSN: 2576-5523
- Journal Of Atmospheric & Earth Sciences | ISSN: 2689-8780
- Journal Of Biotech Research & Biochemistry
- Journal Of Brain & Neuroscience Research
- Journal Of Cancer Biology & Treatment | ISSN: 2470-7546
- Journal Of Cardiology Study & Research | ISSN: 2640-768X
- Journal Of Cell Biology & Cell Metabolism | ISSN: 2381-1943
- Journal Of Clinical Dermatology & Therapy | ISSN: 2378-8771
- Journal Of Clinical Immunology & Immunotherapy | ISSN: 2378-8844
- Journal Of Clinical Studies & Medical Case Reports | ISSN: 2378-8801
- Journal Of Community Medicine & Public Health Care | ISSN: 2381-1978
- Journal Of Cytology & Tissue Biology | ISSN: 2378-9107
- Journal Of Dairy Research & Technology | ISSN: 2688-9315
- Journal Of Dentistry Oral Health & Cosmesis | ISSN: 2473-6783
- Journal Of Diabetes & Metabolic Disorders | ISSN: 2381-201X
- Journal Of Emergency Medicine Trauma & Surgical Care | ISSN: 2378-8798
- Journal Of Environmental Science Current Research | ISSN: 2643-5020
- Journal Of Food Science & Nutrition | ISSN: 2470-1076
- Journal Of Forensic Legal & Investigative Sciences | ISSN: 2473-733X
- Journal Of Gastroenterology & Hepatology Research | ISSN: 2574-2566
- Journal Of Genetics & Genomic Sciences | ISSN: 2574-2485
- Journal Of Gerontology & Geriatric Medicine | ISSN: 2381-8662
- Journal Of Hematology Blood Transfusion & Disorders | ISSN: 2572-2999
- Journal Of Hospice & Palliative Medical Care
- Journal Of Human Endocrinology | ISSN: 2572-9640
- Journal Of Infectious & Non Infectious Diseases | ISSN: 2381-8654
- Journal Of Internal Medicine & Primary Healthcare | ISSN: 2574-2493
- Journal Of Light & Laser Current Trends
- Journal Of Medicine Study & Research | ISSN: 2639-5657
- Journal Of Modern Chemical Sciences
- Journal Of Nanotechnology Nanomedicine & Nanobiotechnology | ISSN: 2381-2044
- Journal Of Neonatology & Clinical Pediatrics | ISSN: 2378-878X
- Journal Of Nephrology & Renal Therapy | ISSN: 2473-7313
- Journal Of Non Invasive Vascular Investigation | ISSN: 2572-7400
- Journal Of Nuclear Medicine Radiology & Radiation Therapy | ISSN: 2572-7419
- Journal Of Obesity & Weight Loss | ISSN: 2473-7372
- Journal Of Ophthalmology & Clinical Research | ISSN: 2378-8887
- Journal Of Orthopedic Research & Physiotherapy | ISSN: 2381-2052
- Journal Of Otolaryngology Head & Neck Surgery | ISSN: 2573-010X
- Journal Of Pathology Clinical & Medical Research
- Journal Of Pharmacology Pharmaceutics & Pharmacovigilance | ISSN: 2639-5649
- Journal Of Physical Medicine Rehabilitation & Disabilities | ISSN: 2381-8670
- Journal Of Plant Science Current Research | ISSN: 2639-3743
- Journal Of Practical & Professional Nursing | ISSN: 2639-5681
- Journal Of Protein Research & Bioinformatics
- Journal Of Psychiatry Depression & Anxiety | ISSN: 2573-0150
- Journal Of Pulmonary Medicine & Respiratory Research | ISSN: 2573-0177
- Journal Of Reproductive Medicine Gynaecology & Obstetrics | ISSN: 2574-2574
- Journal Of Stem Cells Research Development & Therapy | ISSN: 2381-2060
- Journal Of Surgery Current Trends & Innovations | ISSN: 2578-7284
- Journal Of Toxicology Current Research | ISSN: 2639-3735
- Journal Of Translational Science And Research
- Journal Of Vaccines Research & Vaccination | ISSN: 2573-0193
- Journal Of Virology & Antivirals
- Sports Medicine And Injury Care Journal | ISSN: 2689-8829
- Trends In Anatomy & Physiology | ISSN: 2640-7752

Submit Your Manuscript: <https://www.herallopenaccess.us/submit-manuscript>